

Significance of Thrombocytosis in Epithelial Ovarian Tumors

Shwetha Ramu^{1*}, Ruchi Sinha²

¹Assistant Professor, Department of Pathology, Basaveshwara Medical College, and Hospital, Chitradurga, India

²Associate Professor, Department of Pathology, Kasturba Medical College, Mangalore, India

*Address for Correspondence: Dr. Shwetha Ramu, Assistant Professor, Department of Pathology, Basaveshwara Medical College and Hospital, Chitradurga, India

Received: 03 July 2017/Revised: 23 August 2017/Accepted: 13 October 2017

ABSTRACT- Thrombocytosis has been reported in association with ovarian tumors and is often a poor prognostic factor. The present study aims to study the incidence of pre-operative thrombocytosis in epithelial ovarian tumors and to correlate it with anemia, serum CA-125 levels, presence or ascites, FIGO staging and tumor histology. Total 160 cases of resected specimens of surface epithelial ovarian tumors (SEOT) received in the Department of Pathology, Kasturba Medical College Mangalore was studied. The preoperative platelet count, haemoglobin levels and serum CA-125 levels were collected. The presence and degree of ascites were assessed. International Federation of Obstetrics and Gynaecology (FIGO) staging was done. The incidence of thrombocytosis and its correlation with the presence of anaemia, elevated CA-125 levels, FIGO stage with the presence and degree of ascites among malignant cases were statistically analyzed. The incidence of pre-operative thrombocytosis was noted more in malignant SEOTs 80% (40/160). The mean pre-operative platelet count in the present study was $321 \times 10^9 /L$. It was more prevalent in serous epithelial ovarian tumors (83.3%) and these findings were statistically significant ($p=0.0001$). There was a statistically significant association of pre-operative thrombocytosis with the presence and degree of ascites and advanced FIGO staging ($p=0.0001$). Pre-operative thrombocytosis is a frequent finding in malignant SEOTs and is associated with other prognostic markers. This implied that thrombocytosis is probably a marker of tumor aggressiveness, and that platelet may have a role in cancer growth and progression. Thus, the presence of pre-operative thrombocytosis has significance as a poor prognosticator in epithelial ovarian tumors.

Key-words- Surface Epithelial Ovarian Tumors (SEOT), Thrombocytosis, CA 125, FIGO staging

INTRODUCTION

Thrombocytosis refers to platelet count above the normal value ($>400 \times 10^9/L$). Thrombocytosis can be primary or secondary. Malignancy is one of the most important causes of secondary thrombocytosis [1,2]. The association between thrombocytosis and malignancies is known [3]. Thrombocytosis has been reported in variety of neoplastic diseases, including Hodgkin lymphoma, sarcoma and several solid tumors such as lung, renal, gastric, breast, pancreatic, colonic, and gynecological malignancies. [4-8]

In ovarian cancer thrombocytosis is a poor prognostic factor in locally advanced disease [9,10]. Chalas *et al.* [11] found thrombocytosis in 56% of the reviewed cases of epithelial ovarian malignancies.

The etiology of neoplastic megakaryopoiesis remains unclear, it might be related to increased platelet production are due to certain cytokines (IL-6, IL-1) and growth factors released by malignant cells. [7]

Platelet aggregates with tumor cells and prevents immune mediated tumor cell clearance. Thrombospondin-1 helps with adhesion of circulating tumor cells to endothelium, extravasations of tumor cells and metastasis [7].

In an attempt for better understanding the importance of thrombocytosis in epithelial ovarian tumors, we studied the association of thrombocytosis with CA 125 and other prognostic markers.

MATERIALS AND METHODS

In the present study, 160 cases of epithelial ovarian tumors were studied prospectively between the periods of October 2010 to June 2012 in the Department of Pathology, Kasturba Medical College Mangalore, India. The data were collected regularly during the study period from the case records and laboratory reports at the Kasturba Medical College Hospital. The clinical details, histopathological reports, haematological and biochemical parameters were collected pro forma. Patients with any history of myeloproliferative disorders, acute inflammatory conditions, secondary overt malignancies and splenectomy were excluded from the present study. The data collected in the present study were pre-operative platelet counts, haemoglobin and serum CA-125 levels. All patients underwent staging laparotomy. Tumor stage (FIGO staging), tumor

Access this article online

Quick Response Code



Website:

www.ijlssr.com



DOI: 10.21276/ijlssr.2017.3.6.7

histology with the presence and degree of ascites in patients were noted. Tissue was fixed at 10% buffered formalin, and processed. The routine H & E stained slides of all the cases were reviewed thoroughly and the histopathological findings were recorded. The patients with thrombocytosis were correlated with the presence of anaemia, elevated CA-125 levels.

STATISTICAL ANALYSIS

FIGO stage and presence and degree of ascites among malignant cases were statistically analyzed by Chi-square test and Fisher’s exact test. In the present study, ‘p value’ <0.05 was considered significant for the performed tests. All tabulations or statistical analysis was done using the XLSTAT software.

RESULTS

In the present study, 160 cases of surface epithelial ovarian tumors were studied. Majority of the cases i.e. 28.1% (45/160) were in the fourth decade and the least number of cases i.e. 3.1% (5/160) were in the first and the eight decades. Age of the patients ranged from 17 to 80 years with a mean age of 43.64 years. The mean ages of patients for benign, borderline and malignant cases were 38.85, 46.0 and 53.18 years respectively. The most common symptom was pain abdomen 68.8%. The majority of the cases were benign (64.4%), followed by malignant (50%) and borderline cases (4.4%). Serous ovarian tumors (70.6%) were the most common histologic type, followed by mucinous (27.5%) tumors. Other tumors include two cases of endometrioid carcinoma and one case of mixed ovarian tumor composed of endometrioid and clear cell carcinoma components.

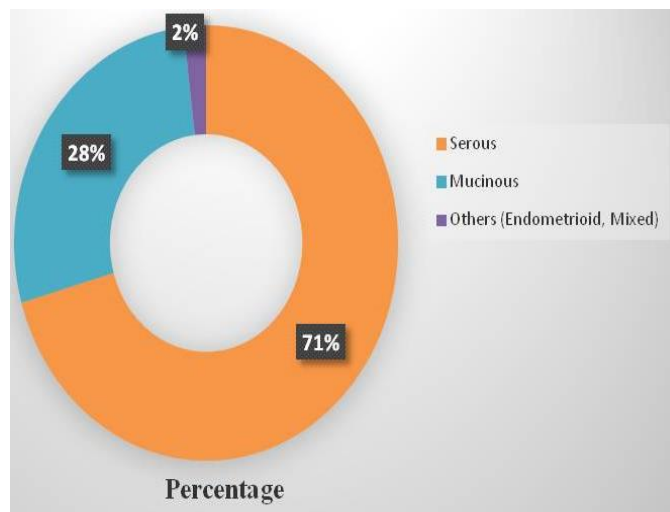


Fig. 2: Distribution of SEOTs according to differentiation

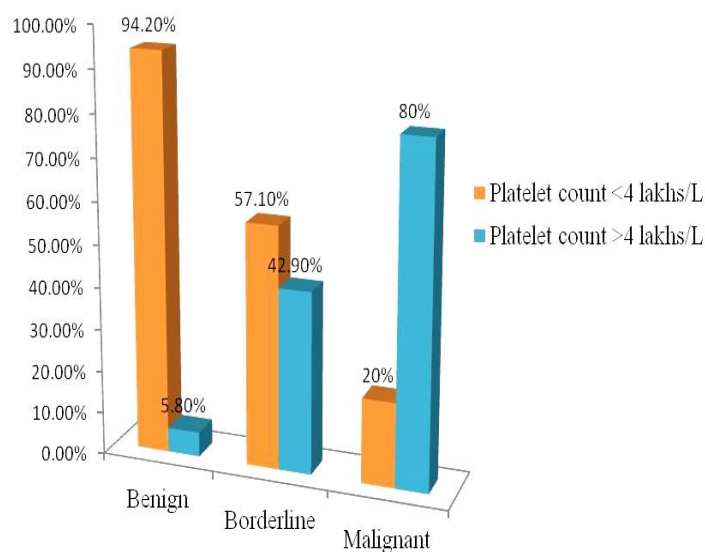


Fig. 3: Correlation of thrombocytosis in SEOTs with malignancy

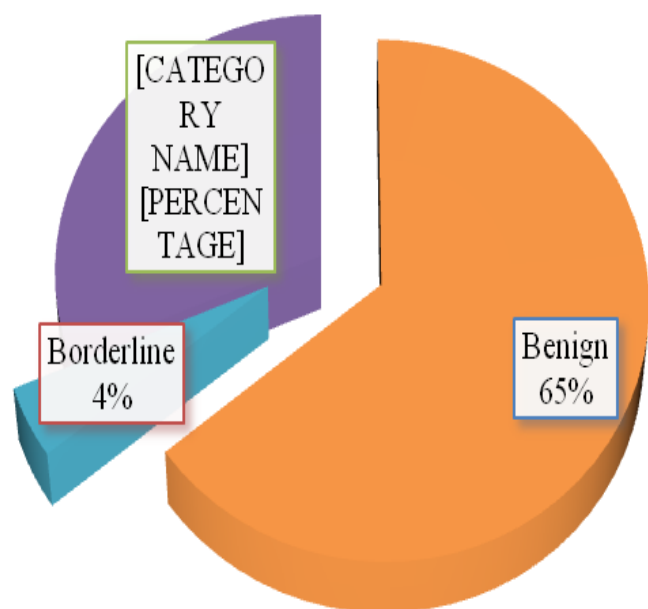


Fig. 1: Distribution of SEOTs as benign, borderline and malignant cases

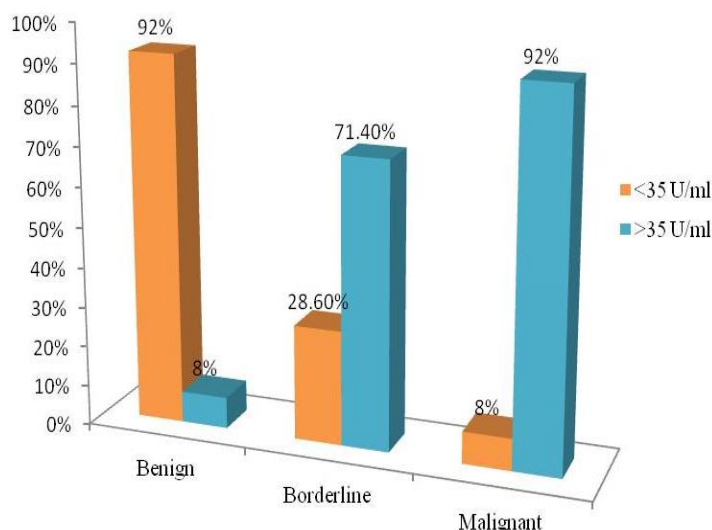


Fig. 4: Correlation of thrombocytosis in SEOTs with CA 125 levels

The platelet count ranged from 172x10⁹ /L to 641x10⁹ /L and mean of the value was 321x10⁹ /L.

DISCUSSION

In our study, thrombocytosis was seen in 49 (30.6%) cases of SEOTs. Total 80% of malignant cases had pre-operative thrombocytosis. Forty seven cases of malignant ovarian tumors had thrombocytosis, and majority of the cases 42(84%) were of serous type. The presence of pre-operative thrombocytosis was more prevalent in serous and mucinous cystadenocarcinomas (83.30%).

The mean platelet count for malignant epithelial ovarian tumors were $435 \times 10^9 /L$, for borderline tumors was $371 \times 10^9 /L$ and for benign tumors was $262 \times 10^9 /L$. Forty (80%) out of fifty cases of malignant surface epithelial ovarian tumors had pre-operative thrombocytosis. Levin and Conley^[2] reported in 1964 that nearly 40% of the patients with inoperable cancer had platelet counts greater than $400 \times 10^9 /L$. A similar study done by Chalas *et al.*^[10] on 241 patients presenting with pelvic mass demonstrated that thrombocytosis was noted in 56% of malignant cases.

Ziomet *et al.*^[9] in their study of 130 patients with epithelial ovarian cancer showed that forty-nine (38%) of ovarian cancer patients had thrombocytosis. Kerpsack and Finan^[11] reported that out of 87 patients, who had a malignant pelvic mass, 54.2% of malignant epithelial ovarian tumors had thrombocytosis as compared to 22.6% of benign epithelial tumors.

Li *et al.*^[5] found that 41 (22.4%) out of 183 women with epithelial ovarian carcinomas had thrombocytosis at presentation with a mean platelet count was $542 \times 10^9 /L$, which was higher than in the present study.

Forty six cases of malignant ovarian tumors had elevated serum CA-125 level, and majority of the cases (87%) were of serous type. Thirty eight (95%) cases of malignant ovarian tumors had elevated serum CA-125 levels. In our study, serum CA-125 levels more than 35 U/ml was considered abnormal. The mean serum CA-125 level in this study was 508 U/ml (range 1.06 U/ml-12750 U/ml). The mean values of serum CA-125 for malignant, borderline and benign epithelial ovarian tumors were 1579 U/ml (range 21.36 U/ml-12750 U/ml), 112 U/ml (range 23 U/ml-376 U/ml) and 15.17 U/ml (range 1.06 U/ml-78 U/ml), respectively.

Higher CA-125 level was seen in malignant (92%) and borderline epithelial ovarian tumors (71.40%) when compared with benign (8%) tumors.

Similar to our study, Schilthuis *et al.*^[19] had elevated pre-operative serum CA-125 levels in 44 of 46 (96%) patients with epithelial ovarian cancer, which is lower in our study. Their serum CA-125 levels ranged from 36 U/ml to 8670 U/ml. They also found that there was a high prevalence of elevated serum CA-125 levels among serous cystadenocarcinoma followed by mucinous cystadenocarcinoma. Correlation of serum CA-125 and tumor stage was found.

Majority of surface epithelial ovarian carcinomas were in stage III (72%) followed by stage IV (14%). Thirty nine out of forty cases of malignant ovarian tumors with thrombocytosis were in advanced stage of disease (stage III /stage IV) and one (2.5%) case, which was in stage II

disease. Thirty two (80%) cases were in stage III and seven (17.5%) cases were in stage IV.

Pre-operative thrombocytosis is associated with many malignancies including ovarian neoplasia. Similar to the present study by Chalas *et al.*^[10] on 241 patients with pelvic masses found that majority of the cases were in stage III (39 cases) and stage IV (22 cases) followed by stage I (11 cases) and stage II (2 cases). Li *et al.*^[5] in their study on 183 ovarian cancer patients found that one hundred forty-four cases (78.7%) were diagnosed with stage III or stage IV disease, and 39 cases (21.3%) were diagnosed with stage I or stage II disease, which was similar to our study.

In present study, the pre-operative thrombocytosis in malignant ovarian tumors were associated with elevated serum CA-125 levels (95%), advanced FIGO stages III (80%) and IV (17.5%), and histologic type. Lund *et al.*^[14] in their study on ovarian cancer patients found a significant linear association between pre-operative platelet count and stage, which was similar to the current study. Thrombocytosis was associated with higher serum CA-125 levels compared with normal platelet count ($p < 0.001$).

The prevalence of thrombocytosis was 24% and 27% in patients with FIGO stages I and II respectively and increased to 39% and 69% in patients with stages III and IV, respectively. They noted no significant differences in the occurrence of thrombocytosis and histologic type. Li *et al.*^[5] in their study on epithelial ovarian cancer patients showed that patients with thrombocytosis were found to have statistically greater elevations of pre-operative serum CA-125 levels ($p = 0.026$), which was not similar to the present study ($P = 0.174$). Also thrombocytosis was statistically associated with advanced stage disease ($p = 0.016$). These findings were similar to the current study. Similar to our study, Bozkurt *et al.*^[13] reported that 16 out of 37 patients had thrombocytosis with stage III and 1 out of 37 patients with stage IV epithelial ovarian malignancies.

CONCLUSIONS

We were studied 160 cases of surface epithelial ovarian tumors comprising of 103 benign, 7 borderline and 50 malignant cases. Majority of the malignant ovarian tumors had statistically significant pre-operative thrombocytosis when compared to borderline and benign tumors. Pre-operative thrombocytosis and concomitant raised CA 125 levels was more prevalent in serous cystadenocarcinoma. Pre-operative thrombocytosis and raised CA 125 levels also correlated with advanced FIGO stage. This implies that pre-operative thrombocytosis is useful as a marker of tumor aggressiveness along with CA 125 levels, implying that platelet may have a role in cancer growth and progression. Further the role of platelets in evolution of metastasis of ovarian tumors needs to be studied.

REFERENCES

- [1] Griesshammer M, Bangerter M, Sauer T, Wennauer R, Bergmann L, et al. Aetiology and clinical significance of thrombocytosis: analysis of 732 patients with an elevated platelet count. *J. Int. Med.*, 1999; 245(3): 295-300.
- [2] Crasta JA, Premalatha TS, Krishnan SM, Vallikad E, kumar R. Significance of preoperative thrombocytosis in epithelial ovarian cancer. *Ind. J. Pathol. Microbiol.*, 2010; 53: 54-56.
- [3] Gucer F, Tamussino K, Keil F, Balkanli-Kaplan P, Yuce MA. Thrombocytosis in gynecologic malignancies. *Anticancer Res*, 2004; 24: 2053-60.
- [4] Levin J, Conley CL. Thrombocytosis associated with malignant disease. *Arch. Int. Med.*, 1964; 114: 497-500.
- [5] Li AJ, Madden AC, Cass I, Leuchter RS, Lagasse LD, et al. The prognostic significance of thrombocytosis in epithelial ovarian carcinoma. *Gynecol Oncol*, 2004; 92: 211-14.
- [6] Tranum BL, Haut A. Thrombocytosis: platelet kinetics in neoplasia. *J. Lab. Clin. Med.*, 1974; 84: 615-19.
- [7] Soonthornthum T, Suraseraneewong V, Kengsakol K, Wijathum K, Kasemsan P, et al. Thrombocytosis in advanced epithelial ovarian cancer. *J. Med. Assoc. Thai.*, 2007; 90: 1495-500.
- [8] Lavie O, Comerçi G, Daras V, Bolger BS, Lopes A, et al. Thrombocytosis in women with vulvar carcinoma. *Gynecol Oncol.*, 1999; 72(1): 82-86.
- [9] Zeimet AG, Marth C, Muller-Holzner E, Daxenbichler G, Dapunt O. Significance of thrombocytosis in patients with epithelial ovarian cancer. *Am. J. Obstet Gynecol.*, 1994; 170: 549-54.
- [10] Kerpsack JT, Finan MA. Thrombocytosis as a predictor of malignancy in women with a pelvic mass. *J. Reprod. Med.*, 2000; 45: 929-32.
- [11] Gupta G P, Massague J. Platelets and metastasis revisited: a novel fatty link. *J. Clin. Invest.*, 2004; 114: 1691-93.
- [12] Chalas E, Welshinger M, Engellener W, Chumas J, Barbieri R, Mann WJ. The clinical significance of thrombocytosis in women presenting with a pelvic mass. *Am. J. Obstet. Gynecol.*, 1992; 166: 974-77.
- [13] Plante M, Rubin SC, Wong GY, Federici MG, Finstad CL, et al. Interleukin-6 level in serum and ascites as prognostic factors in patients with epithelial ovarian cancer, 1994; 73: 1882-88.
- [14] Lund B, Williamson P. Prognostic factors for outcome of and survival after second-look laparotomy in patients with advanced ovarian cancer *Obstet. Gynecol.*, 1990; 76: 617-22.
- [15] Bozkurt N, Yuce K, Basaran M, Kose F, Ayhan A. Correlation of platelet count with second-look laparotomy results and disease progression in patients with advanced epithelial ovarian cancer *Obstet. Gynecol.*, 2004; 103: 82-85.
- [16] Nathan FE, Hernandez E, Dunton CJ, Treat J, Switalska HI, et al. Plasma thrombospondin levels in patients with gynecological malignancies. *Cancer*, 1994; 73: 2853-58.
- [17] Kappen HJ, Neijt JP. Neural network analysis to predict treatment outcome in patients with ovarian cancer *Ann. Oncol.*, 1993; 4: 31-35.
- [18] Bouanene H, Harrabi I, Ferchichi S, Limem HB, Miled A. Factors predictive of elevated serum CA125 levels in patients with epithelial ovarian cancer. *Bull Cancer*, 2007; 94: E18-E22.
- [19] Schilthuis MS, Aalders JG, Bouma J, Kooi H, Fleuren GJ, et al. Serum CA 125 levels in epithelial ovarian cancer relation with findings at second-look operations and their role in the detection of tumour recurrence. *Br J. Obstet. Gynaecol.*, 1987; 94: 202-07.
- [20] Vander Zee AGJ, De Cuyper EMJ, Limburg PC, De Bruijn HWA, Hollema H, et al. Higher levels of interleukin-6 in cystic fluids from patients with malignant versus benign ovarian tumors correlate with decreased haemoglobin levels and increased platelet counts. *Cancer*, 1995; 75: 1004-09.

**International Journal of Life Sciences Scientific Research (IJLSSR)
Open Access Policy**

Authors/Contributors are responsible for originality, contents, correct references, and ethical issues.

IJLSSR publishes all articles under Creative Commons Attribution- Non-Commercial 4.0 International License (CC BY-NC).

<https://creativecommons.org/licenses/by-nc/4.0/legalcode>



How to cite this article:

Ramu S, Sinha R: Significance of Thrombocytosis in Epithelial Ovarian Tumors. *Int. J. Life Sci. Scienti. Res.*, 2017; 3(6):1467-1470. DOI:10.21276/ijlssr.2017.3.6.7

Source of Financial Support: Nil, **Conflict of interest:** Nil