

Radiographic Study of Frontal Sinus Patterns and Nasal Septum Patterns Emphasizing their Implication in Personal Identification

Pinki Rai^{1*}, Amit Kumar Saxena², Ashima Das³, Bhamini Sharma⁴, Jashanpreet Kaur⁵

¹Assistant Professor Anatomy, Government Medical College and Hospital, Chandigarh, India

²Professor Anatomy & Head, Autonomous State Medical College, Shahjahanpur, India

³Professor Anatomy, SHKM Government Medical College & Hospital, Nuh, India

⁴Tutor, All India Institute of Medical Sciences, Rishikesh, India

⁵Demonstrator, Dr BR Ambedkar State Institute of Medical Sciences, Mohali, India

***Address for Correspondence:** Dr. Pinki Rai, Assistant Professor, Department of Anatomy, Government Medical College and Hospital, Chandigarh, India

E-mail: drpinkianatomy@gmail.com

Received: 23 Apr 2023 / Revised: 25 Jun 2023 / Accepted: 27 Aug 2023

ABSTRACT

Background: Morphometric analysis has been very popular among researchers. In the medical field, morphometric studies have produced significant results in personal identification, differentiating the populations of various races and ethnic backgrounds. This study was intended to evaluate the dimensions of frontal sinus cavities to observe the patterns of frontal sinus & nasal septum. Find out if there is any association between the frontal sinus and nasal septum parameters and their implications in personal identification.

Methods: The data used in the study had to be collected from the archival records of digital X-rays so the study was based on a retrospective study design. Two hundred digital radiographic films were collected from both regions, consisting of 100 males and 100 females. The frontal sinus parameters were used to define the pattern for the nasal septum. Five main patterns were recorded. Data was statistically analyzed and descriptive stats, associations and inferences were generated.

Results: The results revealed that 69% of males and 66% of females had a symmetrical pattern of frontal sinus. Combined use of FSP and NSP revealed interesting results.

Conclusion: The frontal sinus can be used as an adjunct to other firm criteria instead of solely dependent on frontal and nasal sinus septum. However, it can be used to identify the ethnic background of a race.

Key-words: Frontal sinus, Forensics, morphometry, Nasal septum pattern, Personal identification

INTRODUCTION

Archeologists and forensic experts use frontal sinus radiographs to perform the morphometric analysis. Also, physicians frequently suggest as a primary investigation modality. Radiological identification still has a very important role in forensics for personal identification and gender estimation, especially when comparative DNA samples are absent.

Comparison is made among ante-mortem and post-mortem radiographs to identify specific structures.^[1] The radiographs must exhibit features that must be unique to the individual and remain stable over time to be of forensic value. Both of these conditions are fulfilled by the sinuses being studied^[1,2].

Like fingerprints, even the frontal sinus is very unique in every individual, even in monozygotic twins. The development is supposed to be completed at the age of 20^[2].

Frontal sinus assessment by radiographs can be chosen as the skull is hard and retained well during decomposition^[3-7]. Identifications are made using ante-mortem radiographs, if available, as records and comparison are made to identify the individual. Research

How to cite this article

Rai P, et al. Radiographic Study of Frontal Sinus Patterns and Nasal Septum Patterns Emphasizing their Implication in Personal Identification. SSR Inst. Int. J. Life Sci., 2023; 9(5): 3323-3332.



Access this article online

<http://ijls.com/>

studies have confirmed that no two individuals have the same frontal sinus patterns and are not even identical twins^[8-10].

MATERIALS AND METHODS

The location of study population selected for the present study included Mewat and Gurugram districts of Haryana. The digital radiographs included in the present study were procured from two different sources located at different locations as per the need of the study. This Observational study consisted of digital radiographs of 200 participants between the ages of 16 and 55.

The study was retrospective in that data was collected using a quota sampling technique by assembling Archival records of radiograph radiographs from 2013 to 2018.

Frontal sinus is best visible in Caldwell view of radiography so while recruiting the archival records of radiographs, only the radiographs taken in Caldwell view were collected.

Standard Technical specifications were used to obtain a good PA Caldwell view^[11-13].

This view's most visible structures are mainly frontal sinuses, nasal septum, petrous temporal bone, crista galli, and middle and inferior turbinates'.

In Fig. 1, the structures on radiographic film are shown above in Caldwell's view. It can be noticed that inter-sinus septum and outline of cavities of frontal sinus are clearly defined. Scallops are also visible on the upper border of frontal sinus cavities.

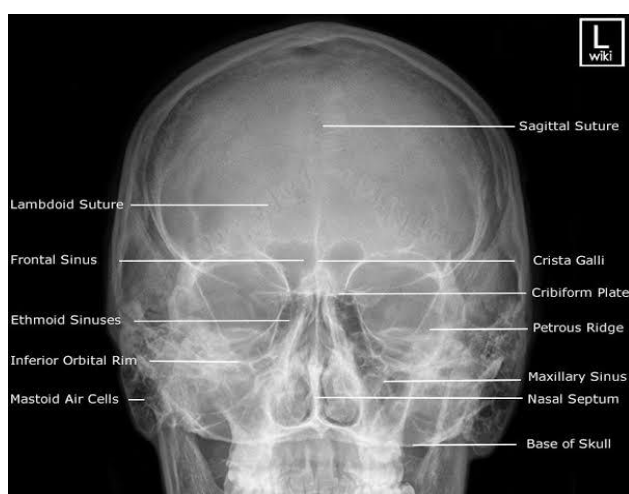

Fig. 1: Visibility of frontal sinus in Caldwell View

Categorization of data- The 200 digital radiographs (PA Caldwell's View) thus collected were composed of 100 radiographs of males and 100 radiographs of females.

Inclusion criteria- Only the radiographs with good image quality and free from any artifact were interpreted. Radiographs of individuals with bilateral complete frontal sinus development were analyzed.

Exclusion criteria- Radiographs exhibiting any pathology like mucous retention within the frontal sinus cavity, syndromic cranial variations, skull deformities, unilateral or bilateral aplasia, or rudimentary frontal sinus excluded from the study.

Parameters studied and method of parameters measurement- Parameters were studied for both the cavities of frontal sinus and pattern of nasal septum. The list of these parameters is given below.

Frontal sinus- Following parameters will be measure for evaluation of frontal sinus.

- Maximum height of right frontal sinus cavity
- Maximum height of left frontal sinus cavity
- Maximum width of right frontal sinus cavity
- Maximum width of left frontal sinus cavity

Method of measurement- The measurements were taken according to the steps described ahead:²The first step was placing the radiograph on the view box and drawing a line directly between both orbital cavities at the naso-frontal suture using a pencil. The width was measured by marking maximum lateral limit from the inter-sinus septum on right and left sides. The maximum height on either side was measured by drawing a parallel line to the naso-frontal line at the highest superior point of that side. The distance between these two parallel lines was measured on either side to get the maximum height (Fig. 2).

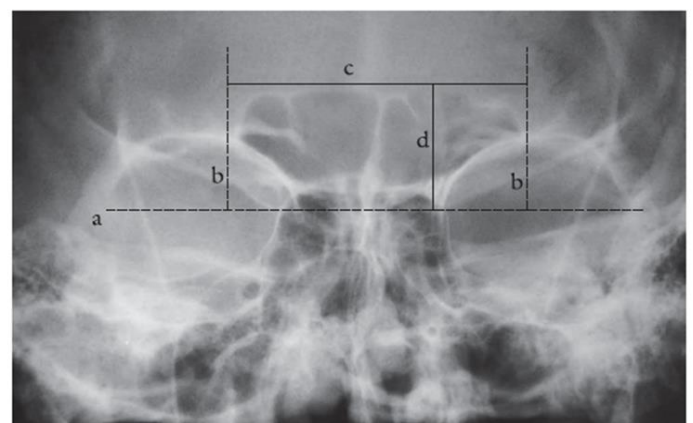


Fig. 2: Measurement of frontal sinus parameters

For all parameters, readings were taken three times and average of them was taken for analysis. The collected data was first filled in proforma and later prepared an Excel sheet.

Calculation of pattern of frontal sinus (symmetry/asymmetry)- For calculation of the pattern of frontal sinus i.e. symmetric or asymmetric, the maximum lateral limit (width) from inter-sinus septum

was measured on both sides. The difference between the two horizontal dimensions was divided by the greatest dimension and multiplied by 100. The percentage less than or equal to 20 was considered symmetrical and more than 20% asymmetrical for the respective side of the cavity^[11,12,14-16]. The calculation formula is shown in the Fig. 3 given below:

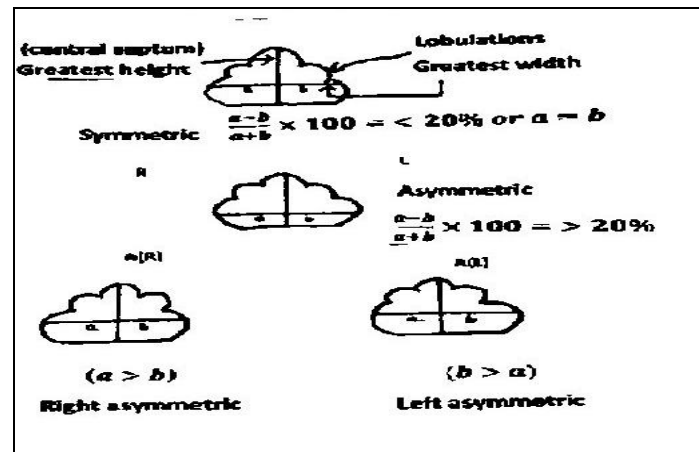


Fig. 3: Assessment of frontal sinus pattern

Nasal septum pattern- Nasal septum is very well visible in Caldwell View. Normally, the septum should be straight, but it is found to be deviated to varying degrees. Five main nasal septum patterns are commonly

observed (Fig. 4). These are straight, deviated to right, deviated to the left, sigmoid i.e. 'S-shaped, reverse sigmoid is a mirror image of sigmoid^[12,14,16].

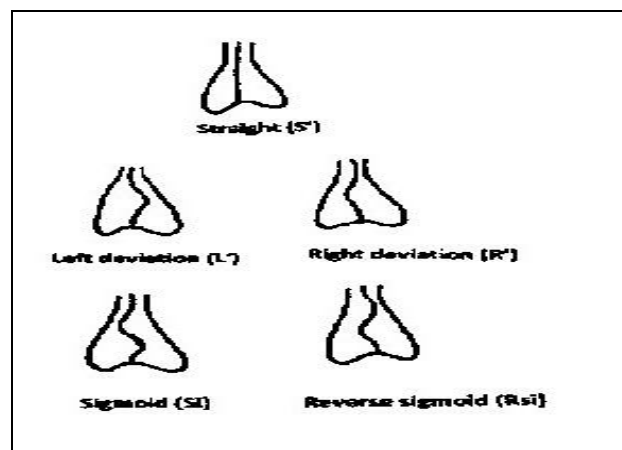


Fig. 4: Patterns of nasal septum

Materials used in the study- Radiograph View box was used to visualize the Caldwell view radiographic films; Markings of the outlines were done using a sharp and pointed HB pencil. Parameters were measured using a measuring scale with millimetre markings and recorded on a data collection sheet.

Statistical Analysis- Parameters manually recorded on the data collection sheet were recorded in digital form using Microsoft excel sheet. Data sets were statically analyzed to obtain Descriptive stats, t-test was used to compare different data sets, ANOVA and normality tests were applied, and analysis was done using IBM SPSS 22.0.

Ethical Approval- The study was duly approved by the Institutional Research Committee (IRC) and Institutional Ethics Committee (IEC) of the SGT University, Gurugram, India, after presentation before the Departmental Research Committee (Letter no. SGTU/FMHS/ANAT/D795).

RESULTS

Data was categorized for all groups, consisting of 50 participants in each group (Table 1). There is an equal number of males and females.

Table 1: Distribution of participants among various groups

Group	Age (Years)	Males	Females	Total
Group-1	16- 25	25	25	50
Group	26-35	25	25	50
Group-1	36-45	25	25	50
Group	46-55	25	25	50

The group-wise distribution of included and excluded participants was observed, as shown in Table 2.

Table 2: Group-wise distribution of cases

Group	Males		Females	
	Included	Excluded	included	excluded
A	24	1	23	2
B	23	2	23	2
C	24	1	24	1
D	23	2	23	2

The parameters observed were the width and height of either side of frontal sinus cavity and symmetry was calculated by the formula described in the methodology section. Patterns of nasal septum were also observed for each group.

The patterns of frontal sinus based on the symmetry of cavity in the first group with age range of 16-25 years is shown in Fig. 5. Symmetrical patterns were predominantly significant in males than in females. Fig. 6 shows the frontal sinus patterns of both sexes among group B (26-35 year). Males exhibited more

symmetrical patterns than females and in females, right frontal sinus cavity presented more asymmetrical patterns.

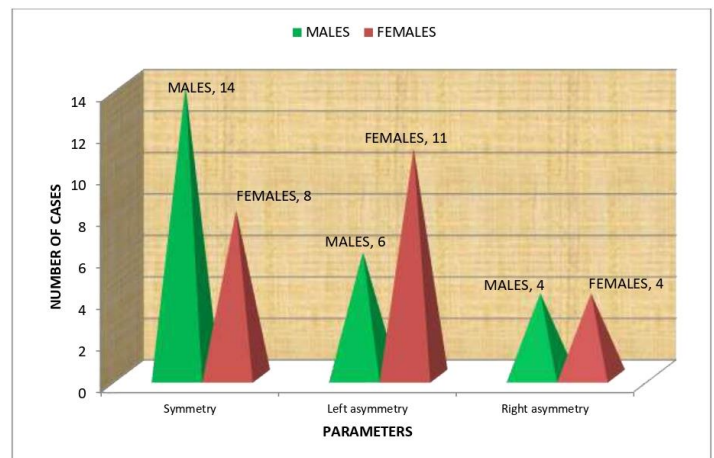


Fig 5: Comparison of Frontal sinus pattern in Group A

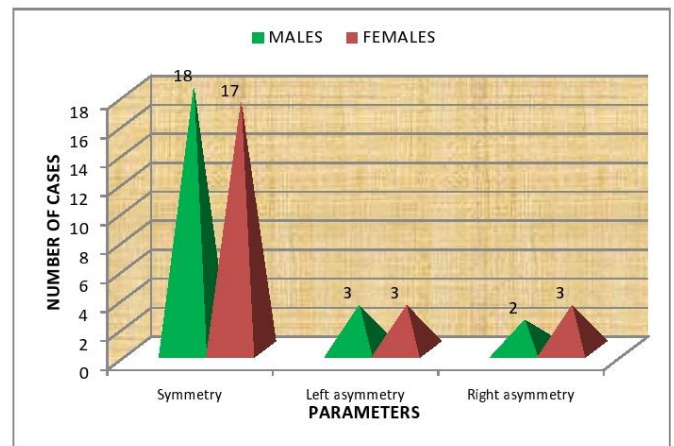


Fig. 6: Comparison of Frontal Sinus Pattern in Group B

Group C (36- 45 year), showed a unique trend in frontal sinus patterns. Here, males were more prone to asymmetrical patterns of left side sinus cavity, and both sexes had equal right asymmetry (Fig. 7).

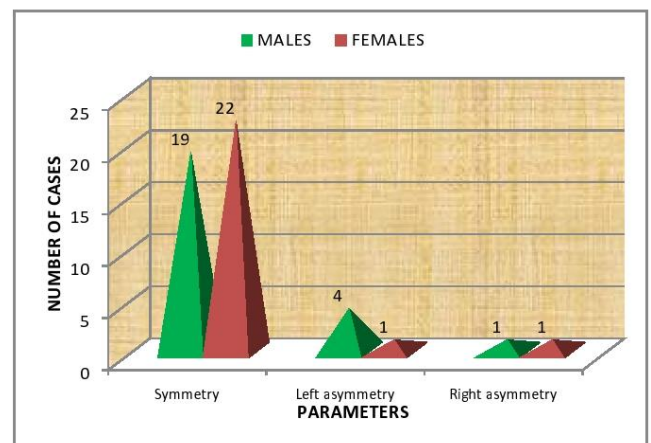


Fig. 7: Comparison of Frontal sinus pattern in Group C

The frontal sinus patterns in last group D (46-55 years) were unique in case both sexes presented almost equally

symmetrical and asymmetrical patterns, as shown in Fig. 8.

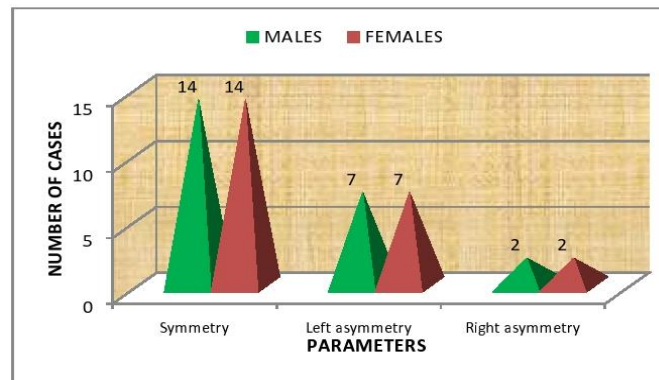


Fig. 8: Distribution of cases according to Frontal sinus pattern in Group D

The results for the analysis of variance among the groups exhibited statically significant results with p-value

<0.0001. However, within the group, no significant differences were seen (Table 3).

Table 3: ANOVA with Frontal Sinus (Inferential)

ANOVA						
		Sum of Squares	df	Mean Square	F	Sig.
Rt. width (cms)	Between Groups	43.83	2	21.91	50.62	<0.0001
	Within Groups	79.65	184	0.43		
	Total	123.48	186			
Lt. width (cms)	Between Groups	3.45	2	1.72	3.53	0.031
	Within Groups	89.84	184	0.48		
	Total	93.29	186			
Rt. height (cms)	Between Groups	1.79	2	0.89	1.34	0.264
	Within Groups	123.18	184	0.66		
	Total	124.97	186			
Lt. height (cms)	Between Groups	0.35	2	0.17	0.30	0.737
	Within Groups	108.18	184	0.58		
	Total	108.53	186			

Combined patterns- Total 14 combinations were found based on frontal sinus and nasal septum patterns. These are shown in Fig. 9.

The comparison tables have been framed to quickly review the present study results and the previous study's

observations. These tables are self-explanatory to compare the results of present and past studies. Table 4 and 5 exhibits the comparison of frontal sinus parameters.

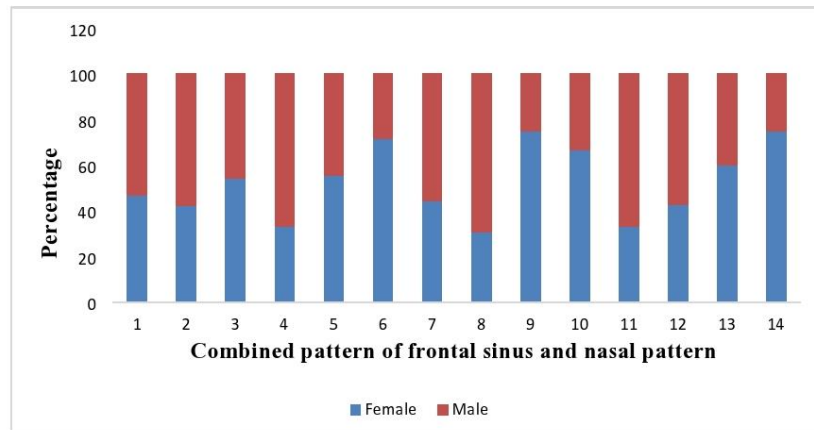


Fig. 9: Combined pattern of frontal Sinus and Nasal Septum

Table 4: Comparison of FS parameters with previous studies

Investigator	Sample size	Mean Age (years)	Avg. FS Width (cm)		Avg. FS Height (cm)	
			Males	Females	Males	Females
Kanjani <i>et al.</i> ^[14]	140	27.3	5.31	3.32	2.12	1.56
Verma <i>et al.</i> ^[12]	80		6.16	3.66	2.08	1.53
Verma <i>et al.</i> ^[18]	149	26.01	5.14	4.23	3.11	2.59
Tehranchi <i>et al.</i> ^[11]	66	19.28	5.52	4.65	2.97	2.66
Belaldvar <i>et al.</i> ^[13]	300	-	2.64	2.22	1.47	1.17
Present study	187	35.3	2.81	2.80	2.9	2.8

Table 5: Comparison of FS and NSP with previous studies

Investigator	Frontal sinus Pattern			Nasal Septum Pattern			
	Sym. (%)	Asym. (%)	Straight (%)	Lt. Dev. (%)	Rt. Dev. (%)	Sig. (%)	Reverse Sig. (%)
Kanjani <i>et al.</i> ^[14]	78.57	21.42	71	13	11	3	2
Verma <i>et al.</i> ^[12]	77.5	22.5	41.25	21.25	27.25	6.25	3.75
Verma <i>et al.</i> ^[18]	78.5	7.3	40.9	2.7	8.05	20.1	28.2
Reddy <i>et al.</i> ^[27]	00	00	92.3	5.76	1.9	00	00
Taniguchi <i>et al.</i> ^[16]	43	57	13.4	37.6	35.3	6.0	6.3
David & Saxena ^[15]	58	32	22	30	42	2.0	2.0
Nagaraj <i>et al.</i> ^[25]	78	22	33	14	21	32	00
Gopal <i>et al.</i> ^[26]	44.75	49	33.75	22.5	30	5	8.75
Present study	67	33	32.62	21.39	26.73	13.36	5.88

DISCUSSION

Morphometric evaluations of bony structures are very popular among researchers for various purposes. Studying the different parameters directly on the bone or by taking their radiographs is equally important in terms of their applications. Radiographic evaluations are more convenient and suitable for keeping and maintaining records for longer durations. In the present study, digital radiographs were used from the available records.

The sample size on which previous studies related to frontal sinus have been performed has shown a broad range. It was observed that the sample size was as available from as small as 40 subjects (20 male, 20 females) ^[17] to as large as 480 subjects ^[11,12,14,18-21]. The present study was carried out on 187 subjects which was more or less comparable to the sample size taken by Kanjani *et al.* ^[14] (140), Soman *et al.* ^[19] (200), Eboh *et al.* ^[29] (216). Many studies had sample size less than or equal to 100 ^[11,12,22-24]. The present study was conducted on the adult frontal sinus cavity, considering that growth is accomplished fully in early adulthood and no further growth occurs after that ^[2]. The range of participant's ages was from 16 years to 55 years. However, this range of age was further divided into four groups on a gap of a decade i.e 16-25, 26-35, 36-45 and 46-55 year. The mean age in the total population was 35.58±11.86 years in males and 35.24±11.34 years in females. The mean age of the sample is comparable to studies included in literature review. The mean ages of previous studies have been reported to be 20 years to 60 years ^[2,11,14,18,19]. The mean age of the present study sample is not far from the range of other studies.

Frontal sinus patterns were studied in terms of symmetrical and asymmetrical presentation of sinus cavity. The present study exhibited that 69% of cases in males have a symmetrical pattern of frontal sinus, while in females, it was accounted for 66% of cases; these results were in congruence with that of a study conducted by Tehranchi *et al.* ^[18] where the investigators found 68% of symmetrical pattern cases among males and 53% of females had symmetrical sinus cavity. The males and females showed symmetry in more than 50% of cases.

Overall, symmetry among the studied population was found in 67% of cases. The results are favoured by David and Saxena ^[15] (58%), Kanjani *et al.* ^[14] (78.57%), Verma

et al. ^[12] (77.5%), Tehranchi *et al.* ^[11] (59%), Nagaraj *et al.* ^[25] (78%). In all these studies, including the present study symmetry was found in more than 50 % of the population. However, few studies have reported the contribution of symmetrical pattern among the population is less than half of the like in studies by Gopal *et al.* ^[26] (44.75%) and Taniguchi *et al.* ^[16] (43%), which are contrasting to the results of this study.

The 33 % of cases in the present study have shown asymmetrical patterns of frontal sinus cavity. A similar pattern was reported by David and Saxena ^[15] with 32%, Verma *et al.* ^[12] at 22.5%, Tehranchi *et al.* ^[11] with 41% and Kanjani *et al.* ^[14] with 32% of cases exhibiting asymmetrical frontal sinus pattern. Although Taniguchi *et al.* ^[16] and Gopal *et al.* ^[26] have documented very high rate of asymmetrical patterns with 57% and 49% of cases. These results are in contrast to the observations made in this study. However, the extremes of results show the wide variety of patterns existing in different populations.

The nasal septum shows extensive variability in its occurrence. Five major types of nasal septum were seen in the present study, though some researchers have observed rare septum patterns, too ^[15,16]. Straight nasal septum was observed in 32.62% of total cases which were by Gopal *et al.* ^[26] (33.75%), Nagaraj *et al.* ^[25], (33%), Verma *et al.* (40.9%) ^[18]. This was the pattern with maximum cases and has been favored by some more researchers where the number of cases with straight septum was the maximum ^[12,14,18,25,26]. In the present study, 26.73 % of total cases had nasal septum deviated towards right. It accounted for the second higher number after straight septum. A similar trend has been reported by Taniguchi *et al.* ^[16] (35.3%) and Gopal *et al.* ^[26] (30%) and Verma *et al.* ^[12] (27.55%). However, David and Saxena reported highest number of cases with right deviated septum (42%) in the study sample ^[15]. Reddy *et al.* ^[25] reported the fewest cases with right deviated nasal septum (1.9%). Apart from the straight nasal septum; the right deviation has shown a great variability in its appearance among different populations ^[14,18,23].

In the present study, left deviation accounted for 21.39% of cases, the third highest number of 22.5% and 21.25 % of Gopal *et al.* ^[26] and Verma *et al.* ^[18], respectively. Pradumen verma and associates observed the lowest number with 2.7% prevalence, followed by Nagaraj *et al.* ^[25] whose results reported 14% of left deviated cases.

Taniguchi *et al.* ^[16] reported to have a maximum number of cases in their study possessed left deviated nasal septum (37.6%) and least had to have a sigmoid pattern (6). They also observed a rare kind of nasal septum pattern that did not match the usually found nasal patterns ^[16].

Sigmoid type of nasal septum was found in 13.36% of subjects in the present study. Other researchers have documented a broad range in the sigmoid type of nasal septum ^[12,18,26,27]. The results recorded in the present study are in unity with other studies where sigmoid nasal septum has been reported to be 20.1 %, 6.25%, 6% and 5%. In the results of another study by Nagaraj *et al.* ^[25], the number of sigmoid septum cases was second highest, with a proportion of 32%, while Reddy *et al.* ^[27] did not observe any single case of sigmoid septum in their study population.

Reverse sigmoid was found to be contributing to 5.88% in the present study. It accounted for the least number of cases in the study sample. In other studies, too, the number of cases with reverse sigmoid was the least of all other types like Kanjani *et al.* ^[14] (1.42%), Verma *et al.* ^[12] (3.75%) and David and Saxena ^[15] (2%). Some studies found no reverse sigmoid septum case in their samples ^[25,27]. However, Verma *et al.* ^[18] had observed the second most found type of nasal septum in their study, contributing to 28.2%. For the present study, the decreasing order type of nasal septum pattern in sequence can be arranged as straight (32.62%), right deviation (26.73%), left deviation (21.39%), sigmoid (13.36%) followed by reverse sigmoid (5.88%) ^[18].

A combination of frontal sinus and nasal septum patterns was obtained to know the distinguishable patterns. When combined, the present study revealed 14 types of combined patterns. The most dominant pattern among males was symmetrical frontal sinus cavities and straight nasal septum pattern, which accounted for 26 cases; among females, symmetrical frontal sinus cavity and nasal septum deviated towards the right side, totalling 20 cases. The present study results were supported by Verma *et al.* ^[12] who observed 9 distinctive combined patterns in a study sample of 80 subjects David and Saxena ^[15] reported 8 classifiable patterns in 34% of individuals and unique in the rest of them. Kanjani *et al.* ^[14] and Taniguchi *et al.* ^[16] have reported many combined patterns, showing 204 different types and 113 types respectively. The differences may be due to varying

sample size and criteria used for classification in these studies.

The variables studied for frontal sinus cavity were treated with logistic regression analysis to assess the overall corrected classification obtained by each parameter. The accuracy in the prediction of sex using right and left width and right and left height were 41.6%, 31.9%, 50.3% and 48.9%, respectively. In a study conducted in Belgaum by Beladvar *et al.* ^[13] the accuracy rate using right and left width and right and left height was found to be 60.4%, and 59.4%, was 60.4%, 64.4%, respectively. In their study, the left side height of the sinus cavity provided the most accurate information while the right-side height provided the maximum accurate results.

When all the parameters were used, the overall accuracy rate came out as 55.7% in present study population. However, it has been seen varying in various populations; both below-average and above average results have been documented ^[13,28] Beladvar *et al.* ^[3] reported 65.5% of correct identification, Eboh *et al.* ^[29] 55% and 59% for left height and left width, Goyal *et al.* ^[28] 60%, Verma *et al.* ^[24] 60%. The present study results for overall accuracy were in congruence with previous studies. Many studies on Indian populations have shown average or slightly above average accuracy in correct identification, like in the present study ^[13,24,28]. But, a very high accuracy rate using frontal sinus parameters and skull measurement i.e. 85.9% in the population of Brazil, has been reported. The diversity in the trend of results from various studies can be due to huge variations in the shape and size of frontal sinus cavities among different populations ^[25,26].

It has been evident from the comparison with previous studies that there cannot be any hard and fast rule for gender identification using frontal sinus dimensions. The variation in results of different populations is remarkable. It can be accurate for identification purposes for one population, while it may not produce even average identification using frontal sinuses. Better management of sinus-related problems, whether disease condition of trauma involving the frontal sinus cavity can be promoted with the knowledge of possible dimensions and patterns of the frontal sinus cavity in the particular population ^[30].

CONCLUSIONS

However, the study provides information about the dependent parameter in this population. The uniqueness of FS and nasal septum pattern can be used to differentiate among the populations and races. For personal identification purposes, mainly in forensics, it can only be used as an adjunct to other firm criteria instead of solely dependent on frontal and nasal sinus septum.

Moreover, the study is carried out on original data and the results are genuine, adding good information to the existing literature. The complete knowledge of the frontal sinus cavity and its dimensions in this population can help physicians manage sinus-related clinical problems.

CONTRIBUTION OF AUTHORS

Research concept- Dr Pinki Rai

Research design- Dr Pinki Rai

Supervision- Dr Amit Kumar

Materials- Dr Pinki Rai

Data collection- Dr Pinki Rai

Data analysis and interpretation- Dr. Pinki Rai & Ms. Bhamini Sharma

Literature search- Ms. Jashanpreet Kaur & Bhamini Sharma

Writing article- Dr Pinki Rai

Critical review- Ms. Jashanpreet Kaur & Bhamini Sharma

Article editing- Dr Ashima Das

Final approval- Dr Amit Kumar

REFERENCES

- [1] Mohan V, Kumar JS, Kumar SC, et al. Morphometric evaluation of frontal sinus in relation to gender- A forensic study. *University J Dent Sci.*, 2015; 1(2): 7-11.
- [2] Rubira bullen IR, Rubira CM, Sarmento VA, Azevedo RA. Frontal sinus size on facial plain radiographs. *J Morphol Sci.*, 2010; 27: 77-81.
- [3] Fernandes CL. A Volumetric Analysis of the Maxillary Sinuses of Zulu and European Crania by Helical Multi slice Computed Tomography. *J Laryngol Otol.*, 2004; 118: 877-81.
- [4] Campobasso CP, Dell'Erba AS, Belviso M, Di Vella G. Craniofacial identification by comparison of antemortem and postmortem radiographs: two case reports dealing with burnt bodies. *Am J Forensic Med Pathol.*, 2007; 28(2): 182-86.
- [5] Cakur B, Sumbullu MA, Durna NB. Aplasia and agenesis of the frontal sinus in Turkish individuals: A retrospective study using dental volumetric tomography. *Int J Med Sci.*, 2011; 8(3): 278-82.
- [6] Duque CS, Casiano RR. *Surgical Anatomy and Embryology of the Frontal Sinus*. 1st Ed., Heidelberg; Springer Berlin: 2005: 21-31. doi: 10.1007/3-540-27607-6_3.
- [7] Hamed SS, Badrawy AM and Fattah SA Gender identification from frontal sinus using multi-detector computed tomography. *J Forensic Radiol Img.*, 2014; 2(3): 117-20.
- [8] Neskey D, Eloy JA, Casiano RR. Nasal, Septal and Turbinate Anatomy and Embryology. *Otolaryngol Clin N Am.*, 2009; 42: 193-205. doi: 10.1016/j.otc.2009.01.008.
- [9] Tang JP, Hu DY, Jiang FH, Yu XJ. Assessing forensic applications of the frontal sinus in a Chinese Han population. *Forensic Sci Int.*, 2009; 183: 1041-43.
- [10] Rai P, Kumar P, Kaur J, Sharma B. Frontal Sinus Cavities and Sex Determination: A Narrative Review. *Acta Scientific Med Sci.*, 2023; 7(9): 98-107.
- [11] Tehranchi A, Saedi S, Motamedian SR, Rohani K. Radiographic Evaluation of Frontal Sinus Dimensions and Anatomic Variations. *J Med Med Res.*, 2016; 8(5): 454-62.
- [12] Verma K, Nahar P, Singh MP, Mathur H, et al. Use of Frontal Sinus and Nasal Septum Pattern as an Aid in Personal Identification and Determination of Gender: A Radiographic Study. *J Clin Diagn Res.*, 2017; 11(1): ZC71-74.
- [13] Belaldavar C, Kotrashetti VS, Hallikerimath SR, Kale AD. Assessment of frontal sinus dimensions to determine sexual dimorphism among Indian adults. *J Forensic Dent Sci.*, 2014; 6(1): 25-30.
- [14] Kanjani V, Annigeri RG, Revanappa MM, Tejaswini NG, et al. Morphometric Evaluation of the Frontal Sinus and Nasal Septum as an Aid in Personal and Gender Identification- A Retrospective Digital Radiographic Study. *JMSCR*, 2018; 6(3): 1154-61.
- [15] David MP, Saxena R. Use of frontal sinus and nasal septum patterns as an aid in personal identification: A digital radiographic pilot study. *J Forensic Dent Sci.*, 2010; 2: 77-80.

- [16]Tanigichi M, Sakoda S, Kano T, Zhu BL, Kamikodai Y, et al. Possible use of nasal septum and frontal sinus patterns to radiographic identification of unknown human remains. *Osaka City Med J.*, 2003; 49: 31-38.
- [17]Mathur H, Mathur A, Ahmed J, Khorate M, Tripathi P. Conventional frontal sinus imaging in identification of sex: Original study in population of Udaipur city, India. *J Med Sci Clin Res.*, 2013; 1(1): 33-37.
- [18]Verma P, Verma KG, Khosa R, Kumar S, Basavaraju S, et al. Combined use of frontal sinus and nasal septum patterns as an aid in forensics: A digital radiographic study. *North American J Med Sci.*, 2015; 7(2): 47-52.
- [19]Soman BA, Sujatha GP, Lingappa A. Morphometric evaluation of the frontal sinus in relation to age and gender in subjects residing in Davangere, Karnataka. *J Forensic Dent Sci.*, 2016; 8: 1-5.
- [20]Pandeshwar P, Kumar NN, Shastry SP, Ananthaswamy A, et al. Sexual Dimorphism of Radiomorphological Features of Frontal Sinus. Sexual dimorphism of radiomorphological features of frontal sinus. *Int J Forensic Odontol.*, 2017; 2 :46-50.
- [21]Marana AN, Oura DY, Yamamoto T, Falguera FPS, et al. Towards an Automatic Frontal Sinus Identification System` Anais do II Workshop de Visão Computacional, USP-São Carlos., 2006; pp. 93-98.
- [22]Prashar A, Sharma VP, Singh GK, Singh GP, Sharma N, et al. A Cephalometric Study Of Frontal Sinus And Its Relation With Craniofacial Patterns. *Indian J Denl Sci.*, 2012; 5(4): 4-8.
- [23]Cameriere R, Ferrante L, Molleson T, Brown B. Frontal sinus accuracy in identification as measured by false positives in kin groups. *J Forensic Sci.*, 2008; 53: 1280-82.
- [24]Verma S, Mahima, VG, Karthikeya, P, Radiomorphometric analysis of frontal sinus for sex determination. *J Foren Dent Sci.*, 2014: 6(3): 177-82.
- [25]Nagaraj T, Nigam H, Santosh HN, Sumana CK, Gogula S, et al. Personal identification using frontal sinus and nasal septum patterns in forensic medicine: A retrospective digital radiographic study. *J Med Radiol Pathol Surg.*, 2017; 4: 5–8.
- [26]Gopal S, Vijayan P. The Significance of frontal sinus and nasal septum patterns in personal identification in forensics: A retrospective CBCT study. *Inter J Oral Med Res.*, 2016; 2(6): 57-61.
- [27]Reddy S, Rajesh N, Raghavendra MN, Alapati S, Kotha P. Unleash the unknown-Frontal sinus and nasal septum patterns in personal identification. *Int J Dent Sci Res.*, 2014; 2: 141 5.
- [28]Goyal M, Acharya AB, Sattur AP, Naikmasur VG. Are frontal sinuses useful indicators of sex?. *J Forensic Leg Med.*, 2013; 20: 91-4.
- [29]Eboh DE, Ogbeide OU, Ivwighren T. Radiographic anthropometric study of frontal sinus for sex determination in Benin city, South-South Nigeria. *J Forensic Dent Sci.*, 2017; 9:31-5.
- [30]Rai P, Saxena A, Mehrotra N, Aneja P. Morphometric Analysis of Frontal Sinus Dimensions Using Digital Radiographs. *Inter J Res Pharmaceutical Sci.*, 2020; 6023-27. doi: 10.26452/ijrps.v11i4.3267.

Open Access Policy:

Authors/Contributors are responsible for originality, contents, correct references, and ethical issues. SSR-IJLS publishes all articles under Creative Commons Attribution- Non-Commercial 4.0 International License (CC BY-NC). <https://creativecommons.org/licenses/by-nc/4.0/legalcode>

