

Proximal Humeral Epiphyseal Fusion for Age Estimation: A Cross-Sectional Study from Chennai

Nirmal Kumar¹, Janani S^{2*}, Gokulakrishnan A³, Priyatharshini K⁴, Balasubramanian S⁵

¹Assistant Professor, Department of Forensic Medicine, Government Medical College, Virudhunagar, India

²Associate Professor, Institute of Forensic Medicine, Madras Medical College, Chennai, India

³Associate Professor, Department of Forensic Medicine, Government Medical College, The Nilgiris, India

⁴Professor and Head, Department of Forensic Medicine, Government Stanley Medical College, Chennai, India

⁵Professor and Head, Department of Forensic Medicine, Indira Medical College, Chennai, India

***Address for Correspondence:** Dr. Janani S, Associate Professor, Institute of Forensic Medicine, Madras Medical College, Chennai, India

E-mail: janyraj@gmail.com

Received: 10 Oct 2025 / Revised: 17 Dec 2025 / Accepted: 25 Feb 2026

ABSTRACT

Background: Age estimation of an individual is of medico-legal importance in both civil & criminal cases. Ossification centres appear & fuse in a fairly definite sequence at a particular age group from which the age of an individual can be determined. Extensive work on age determination has been carried out across different states of India, revealing differences in the age of the epiphyseal union. The difference may be due to varying geographic, dietary, hereditary, and other factors.

Methods: This study aims to investigate the relationship between the stage of epiphyseal union at the shoulder joint & biological age in the Chennai population. The study population comprises healthy subjects aged 13 to 20 years. On examination of 130 radiographs of the shoulder joint, the age of complete fusion of the epiphysis of the proximal end of the humerus was 17-18 years for males and 16-17 years for females.

Results: Complete fusion occurred at 17–18 years in males and 16–17 years in females, indicating earlier skeletal maturity in females. The proportion of individuals with complete fusion increased progressively with age in both sexes. Among younger age groups, minimal fusion was observed, whereas by late adolescence, a majority of females and a substantial proportion of males exhibited complete fusion. These findings confirm that proximal humeral epiphyseal fusion is a reliable marker for age estimation in late adolescence and early adulthood.

Conclusion: Radiological assessment of the proximal humeral epiphysis provides a minimally invasive and reliable method for estimating age. Fusion occurs earlier in females by 1–2 years, highlighting the importance of sex-specific evaluation. The results provide population-specific reference data for Chennai, aiding forensic age determination in medico-legal cases.

Key-words: Age estimation, Fusion, Humerus, Ossification centres, Shoulder joint

INTRODUCTION

Determining an individual's age is an absolute mandate, whether the individual is living, dead, or represented by human remains, and is a vexing problem for medical jurists in both civil and criminal matters.

Lack of uniform guidelines or procedures globally is one of the key problems in Forensic Medicine and Anthropology. Western associations have been attempting to review practices across countries and address issues like ageing, post-mortem interval, etc. ^[1]

Ageing in the forensic context is extremely important for both the dead and the living. After death, it helps identify the deceased and narrow down suspects for comparison with missing persons. In the case of living individuals, age is required in several civil and criminal matters. It has to be kept in mind that the older the person is, the less accurate the methods are, and the age would be estimated with a wider error range. ^[1]

How to cite this article

Kumar N, Janani S, Gokulakrishnan A, Priyatharshini K, Balasubramanian S. Proximal Humeral Epiphyseal Fusion for Age Estimation: A Cross-Sectional Study from Chennai. SSR Inst Int J Life Sci., 2026; 12(2): 9554-9560.



Access this article online

<https://ijls.com/>

Even though research is ongoing across several methodologies, the commonly used methods for age estimation are physical, dental, and skeletal.^[1] Extensive work on age determination has been carried out across different states of India, revealing differences in the age of the epiphyseal union. The difference may be attributed to several factors, including varying geographic, dietary, and hereditary factors.^[2]

Identification is established by matching a set of general observations made about the body to an array of general information known to be true about that particular individual. The finding of a specific feature or trait, or a combination of unique features, that is known to be possessed by that individual alone, will add considerable weight to the conclusion and aid in medico-legal practice.^[3,4]

Ossification centres and epiphyseal unions can be examined radiologically or visualized in the dead by dissection. The risks of exposure to X-rays must be weighed against the benefits of the radiological information, and unnecessary examinations must be avoided. Estimation of age from shoulder joint ossification is important because it contains ossification centers that fuse later in life^[2-4]. This makes it highly valuable for estimating age in late adolescence and early adulthood, especially in medico-legal cases where narrowing down age is crucial. The absence of such vital information for our geographic location resulted in this study.

MATERIALS AND METHODS

Study Design and Setting- This cross-sectional observational study was conducted at the Department of Forensic Medicine and Department of Radiology, Government Stanley Medical College, Chennai, from January 2023 to December 2024. The study aimed to investigate the relationship between the stage of epiphyseal fusion of the proximal humerus and chronological age in adolescents and young adults of the Chennai population.

Study Population- A total of 130 healthy individuals aged 13–20 years were recruited. Participants were divided into four age groups based on their reported age, verified by government-issued documents or academic records: 13–15 years, 16–17 years, 17–18 years, and 18–20 years.

Inclusion criteria- Participants were required to have resided in Chennai for at least 5 years, have an accurate date of birth, and be free of disabilities, regional trauma, medical conditions, or endocrine disorders.

Exclusion criteria- Individuals who did not meet the inclusion criteria or were unwilling to participate were excluded.

Radiological Examination- All participants underwent X-ray imaging of the shoulder joint in the anteroposterior (AP) view. Each radiograph was carefully examined for the appearance of ossification centers, progression of epiphyseal fusion, and post-fusion scarring.

The ossification process of the proximal humeral epiphysis was graded into four stages:

Grade I: Centre not appear

Grade II: Centre appeared but incomplete

Grade III: Union started but is incomplete

Grade IV: Complete union

Criteria for fusion

- I. No gap or defect.
- II. No discontinuity in the outline of the bone.
- III. Presence of epiphyseal scar was considered as fused.

Statistical Analysis- Data from all radiographs were entered into Microsoft Excel. Descriptive statistics were used to analyze the stage of epiphyseal fusion across age groups and sexes, with a focus on determining the age at complete fusion in males and females.

Ethical Considerations- The study protocol was approved by the Institutional Ethical Committee before commencement. Written informed consent was obtained from all participants, and the study adhered to institutional ethical standards for research involving human subjects.

RESULTS

A total of 130 radiographs of the shoulder joint were analyzed. Of these, 72 were male and 58 were female. The sex-wise distribution of the study population is shown in Fig. 1.

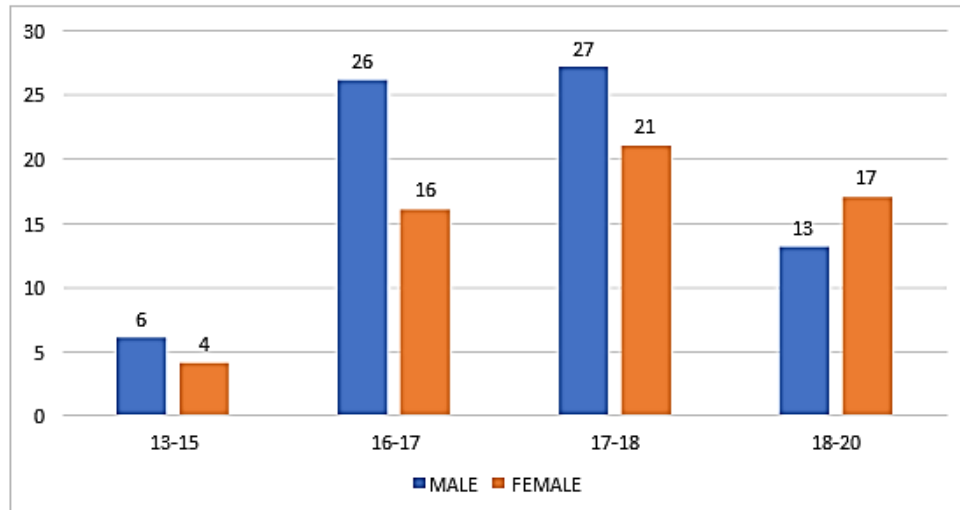


Fig 1: Sex wise distribution of subjects

Among females aged 13–15 years (n = 10), all cases were Grade I, indicating that the secondary ossification centre had not appeared. In the 16–17-year age group (n = 42), 4 cases were Grade I, 5 cases (11.90%) were Grade II, 6 cases (14.28%) were Grade III, and 8 cases (19.04%) were Grade IV, indicating progressive fusion. In the 17–18 years group (n = 21), 2 cases (4.16%) were Grade I, 3

cases (6.25%) were Grade II, 5 cases (10.41%) were Grade III, and 11 cases (22.91%) were Grade IV. Among females aged 18–20 years (n = 17), none were in Grade I; 2 cases (11.76%) were Grade II, 6 cases (35.29%) Grade III, and 9 cases (52.94%) had complete union (Grade IV) (Table 1).

Table 1: Stage of fusion of the epiphysis of the proximal end of humerus among females.

Stage	Grade I	Grade II	Grade III	IV
13-15	04	0	0	0
16-17	04	05	06	08
17-18	02	03	05	11
18-20	00	02	06	09
Total	10	10	17	28

In males aged 13–15 years (n = 6), all cases were Grade I and showed no union. Among males aged 16–17 years (n = 19), 8 cases (19.04%) were Grade I, 6 cases (14.28%) Grade II, and 5 cases (11.90%) Grade III. In the 17–18-year age group (n = 27), 5 cases were Grade I, 5 cases

(10.41%) Grade II, 7 cases (14.58%) Grade III, and 10 cases (20.83%) Grade IV. In the 18–20 years group (n = 13), 2 cases (15.38%) were Grade I, 2 cases (15.38%) Grade II, 4 cases (30.76%) Grade III, and 5 cases (38.46%) showed complete union (Grade IV) (Table 2, Fig. 2).

Table 2: Stage of fusion of the epiphysis of proximal end of humerus among males.

Stage	I	II	III	IV
13-15	06	00	00	00
16-17	08	06	05	00
17-18	05	05	07	10
18-20	02	02	04	05
Total	21	13	16	15

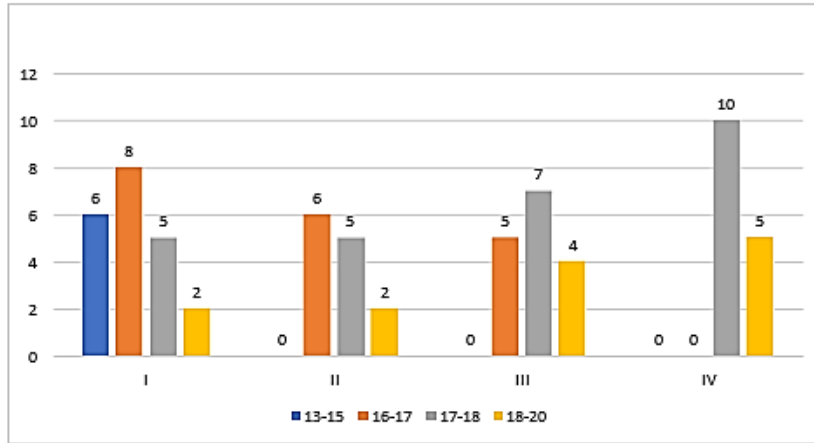


Fig. 2: Stage of fusion of the epiphysis of proximal end of humerus among males.

The age at complete fusion of the proximal humeral epiphysis occurred earlier in females than in males. In males, complete union occurred in 15.38% of cases in the 17–18-year age group and 7.69% in the 18–20-year

age group. Among females, 16.9% of cases in the 17–18 years group and 13.84% in the 18–20 years group showed complete fusion (Table 3, Fig. 3).

Table 3: Age of incidence of complete union

Age Group (years)	No. of Cases	% of Male Cases with complete union among males	% of Female Cases with complete union among females
13-15	10	0%	0
16-17	42	0%	12.3%
17-18	48	15.38%	16.9%
18-20	30	7.69%	13.84%

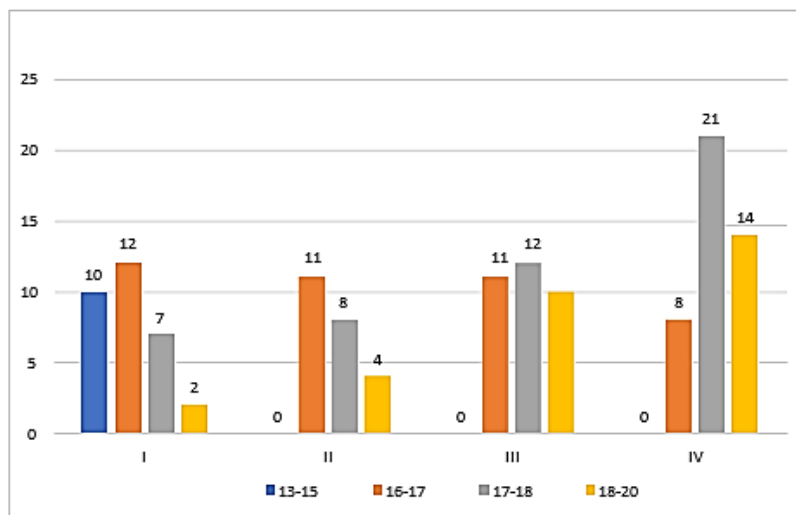


Fig. 3: Stage of fusion of epiphysis of proximal end of humerus

Overall, the data indicate that epiphyseal fusion at the proximal humerus progresses gradually with age, with females achieving complete fusion 1–2 years earlier than

males. The observed pattern aligns with expected skeletal maturation trends in late adolescence and early adulthood in the Chennai population.



DISCUSSION

The present study analyzed proximal humeral epiphyseal fusion in a sample of 130 healthy adolescents and young adults from Chennai and found that the age of complete union differs between sexes, with females showing earlier fusion than males. Complete fusion was observed in females primarily between 16 and 17 years, whereas in males it occurred mainly between 17 and 18 years. This sex difference of 1–2 years aligns with previous studies reporting that epiphyseal centres mature earlier in females than in males [5–7]. Such differences underscore the importance of accounting for sex-specific variation when estimating age using skeletal maturity indicators [8]. The secondary ossification centre of the proximal humerus progresses through predictable stages, beginning with the appearance of the centre, followed by incomplete union, the initiation of fusion, and finally complete union with the presence of an epiphyseal scar. The stepwise progression allows for more accurate estimation of chronological age, particularly in late adolescence when other skeletal indicators, such as wrist and hand bones, may already have fused [7–10]. Radiological assessment of the shoulder joint thus provides a valuable supplementary tool in forensic age estimation, especially for individuals approaching legal adulthood [11].

When compared with other regions in India, the age of complete fusion in the Chennai population appears slightly higher. Saini *et al.* [5] reported complete fusion in males by 16–17 years and in females by 15–16 years, whereas our study shows fusion at 17–18 years in males and 16–17 years in females. This difference may reflect geographic, nutritional, and endocrine influences on skeletal maturation [8–10]. While the impact of diet and socioeconomic status was not directly assessed, previous studies suggest that these factors can contribute to variations in epiphyseal fusion [6,7,9]. Such regional differences underscore the need for population-specific reference data for accurate forensic age estimation [5–12]. Despite the general trends, considerable individual variability exists in the progression of fusion stages. In males aged 18–20 years, some individuals still exhibited early or incomplete fusion, while others had complete union. Similar variability was noted among females, though to a lesser extent. This variability demonstrates the limitations of relying on a single skeletal marker for precise age estimation. The use of multiple ossification

centres, combined with dental and physical assessments, could improve accuracy in forensic investigations [11–12].

Radiological assessment of the shoulder joint is less invasive than postmortem examination and allows repeated evaluation when necessary. However, X-ray exposure involves ionizing radiation, which must be minimized in living adolescents. Emerging modalities, such as magnetic resonance imaging (MRI), provide a radiation-free alternative and have been successfully used to assess proximal humeral fusion [13–17].

The findings have important medico-legal implications. Accurately determining whether an individual has reached 18 years of age is critical in civil and criminal contexts. Conventional methods, including dental, pelvic, and cranial assessments, have limitations due to variability caused by genetic, endocrine, and nutritional factors. Our study demonstrates that radiological evaluation of the proximal humeral epiphysis can serve as a reliable adjunct, helping narrow age estimation to within a 1–2-year range. The earlier fusion observed in females must be accounted for to avoid overestimation or underestimation of age [5–12].

Certain limitations must be acknowledged. The study was conducted at a single centre and focused solely on the shoulder joint, which may restrict generalizability. Large-scale, multicenter studies incorporating multiple skeletal markers, along with dental and physical assessments, are necessary to develop comprehensive age-estimation protocols for the Indian population. Factors such as nutrition, endocrine disorders, and socioeconomic background, which may influence skeletal maturity, were not evaluated and should be considered in future research [8–12].

LIMITATIONS

The current study focused on only one major joint, i.e., the shoulder joint. However, to efficiently determine an individual's age, multiple joints, including dental and physical examinations, must be considered before any opinion can be derived. Also, a large-scale study across multiple centres is needed to identify subtle variations within the local population.

CONCLUSIONS

In conclusion, this study provides population-specific data on the timing and progression of proximal humeral epiphyseal fusion in adolescents and young adults from

Chennai. Females achieve complete fusion earlier than males, and the gradual progression through distinct ossification stages can be reliably assessed radiologically. These findings reinforce the utility of the shoulder joint as a supplementary marker for forensic age estimation in late adolescence and early adulthood. Accurate age assessment using proximal humeral fusion, combined with other skeletal, dental, and physical indicators, enhances the reliability of medico-legal age determination in the Indian context.

CONTRIBUTION OF AUTHORS

Research concept– Nirmal Kumar, Gokulakrishnan A, Balasubramanian S

Research design– Janani S, Priyatharshini K

Supervision– Priyatharshini K, Balasubramanian S

Materials– Not applicable

Data collection– Nirmal Kumar, Gokulakrishnan A

Data analysis and interpretation– Nirmal Kumar, Gokulakrishnan A

Literature search– Janani S

Writing article– Janani S

Critical review– Nirmal Kumar, Janani S, Gokulakrishnan A, Priyatharshini K, Balasubramanian S

Article editing– Nirmal Kumar, Janani S, Gokulakrishnan A, Priyatharshini K, Balasubramanian S

Final approval– Nirmal Kumar, Janani S, Gokulakrishnan A, Priyatharshini K, Balasubramanian S

REFERENCES

- [1] Cunha E, Baccino E, Martrille L, Ramsthaler F, Prieto J, et al. The problem of aging human remains and living individuals: A review. *Forensic Sci Int.*, 2009; 193(1–3): 1–13.
- [2] Bokariya P, Patel S, Sharma V, et al. Effects of dietary habits on epiphyseal fusion. *J Indian Acad Forensic Med.*, 2009; 31(4): 331–33.
- [3] Chaurasia BD. *Human Anatomy: Regional & Applied*. 2nd edition, CBS Publishers, 2010. Available at: <https://dokumen.pub/bd-chaurasias-human-anatomy-volume-2-regional-and-applied-dissection-and-clinical-lower-limb-abdomen-and-pelvis-2-8thnbsped-9388902742-9789388902748.html>.
- [4] Modi's Textbook of Medical Jurisprudence & Toxicology. 23rd edition, 1998. Available at: <https://dokumen.pub/modi-a-textbook-of-medical-jurisprudence-and-toxicology-27th.html>.
- [5] Saini OP, Saini PK, Gupta BM. Fixation of 16 years of age by radiological study of shoulder joint (A Jaipur based study). *J Indian Acad Forensic Med.*, 2005; 27(2): 96–99.
- [6] Buri S, Singh R, Jain M, et al. Determination of age from epiphyseal union of bones at shoulder joint in boys in Bikaner region. *J Indian Acad Forensic Med.*, 2011; 33(1): 15–18.
- [7] Patil A, Shinde S, Kulkarni R, et al. Age estimation using digital radiography of epiphysial union of shoulder joint. *J Pharm Negat Results.*, 2022; 13(8): 23–29.
- [8] Parkhe S, Patel R, Gohil P, et al. A study of age estimation from digital X-ray of shoulder joint in south Gujarat region. *MedPulse Int J Forensic Med.*, 2021; 17(1): 1–5.
- [9] Saravanan DS, Julius R, Angayarkanni S. Determination of age by radiological examination of shoulder joint. *IP Int J Forensic Med Toxicol Sci.*, 2023; 7(3): 94–99.
- [10] Mazumder A, Nagrale N. Estimation of age from shoulder joint by radiographic assessment of epiphyseal fusion of related bones in population of Chhattisgarh: A cross sectional study. *Medico-legal Update.*, 2019; 19(2): 7–11.
- [11] Patani KC, Bhatt R, Shah P, et al. Determination of age from shoulder joint by radiological examination of epiphyseal union of proximal end of humerus in boys from Ahmedabad region. *Indian J Forensic Med Toxicol.*, 2021; 15(2): 50–54.
- [12] Srivastva M, Ashwani RK. Determination of age by studying radiological fusion of shoulder joint in relation to birth certificates in 16–20 years age group. *Int J Med Phar Drug Res.*, 2022; 36: 45–49.
- [13] Tirpude B, Ramteke A, Joshi R, et al. Age determination from epiphyseal union of bones at shoulder joint in boys of central India. *Indian J Forensic Med Pathol.*, 2016; 9(3): 133–36.
- [14] Tirpude B, Ramteke A, Joshi R, et al. Age determination from epiphyseal union of bones at shoulder joint in girls of central India. *J Forensic Med Sci Law.*, 2014; 23(1): 12–15.
- [15] Singh A, Singh DK, Paricharak H, Pant H. Estimation of age by x-ray examination of distal end of humerus. *J Evol Med Dent Sci.*, 2014; 3(35): 9286–303.

- [16]Ekizoglu O, Saygi B, Ates O, et al. Forensic age diagnostics by magnetic resonance imaging of the proximal humeral epiphysis. *Int J Legal Med.*, 2019; 133(1): 249–56.
- [17]Santoro V, De Donno A, Marrone M, Campobasso CP, Introna F. Forensic age estimation of living individuals: a retrospective analysis. *Forensic Sci Int.*, 2009; 193(1–3): 129–34.

Open Access Policy:

Authors/Contributors are responsible for originality, contents, correct references, and ethical issues. IJLSSR publishes all articles under Creative Commons Attribution- Non-Commercial 4.0 International License (CC BY-NC). <https://creativecommons.org/licenses/by-nc/4.0/legalcode>

