

Assessment of Acromion Morphology in Association with Shoulder Impingement Syndrome using MRI

Abhisek Dash¹, Chandra Sekhar Pradhan², Gopal Chandra Patro^{3*}, Jyotibhanja Das⁴

¹Senior Resident, Department of Orthopaedic Surgery, SLN Medical College and Hospital, Koraput, Odisha, India

²Associate Professor, Department of Orthopaedic Surgery, MKCG Medical College and Hospital, Berhampur, Odisha, India

³Senior Resident, Department of Orthopaedic Surgery, MKCG Medical College and Hospital, Berhampur, Odisha, India

⁴Junior Resident, Department of Orthopaedic Surgery, MKCG Medical College and Hospital, Berhampur, Odisha, India

***Address for Correspondence:** Dr. Gopal Chandra Patro, Senior Resident, Department of Orthopaedic Surgery, MKCG Medical College and Hospital, Berhampur, Odisha, India

E-mail: gopal8694patro@gmail.com

Received: 07 Jun 2023 / Revised: 14 Aug 2023 / Accepted: 11 Oct 2023

ABSTRACT

Background: The third most common musculoskeletal symptom in orthopaedic clinical practice is a sore shoulder, which can cause significant morbidity. It has been reported that 7–27% of the general population has it, and 36–66% of overhead arm athletes have it. Pathophysiology includes functional, degenerative, and mechanical factors. Most shoulder pain is subacromial pain syndrome (SAPS), often known as ‘shoulder impingement syndrome’. Impingement hypothesis: shoulder joint structures mechanically clash. SAPS accounts for 36–48% of shoulder discomfort.

Methods: This observational study was conducted in the Department of Orthopaedics, MKCG Medical College and Hospital, Berhampur, among Eastern Indian outpatients. The study included adult patients (ages 18–75) of both sexes who presented to MKCG Medical College and Hospital's OPD with shoulder pain from December 2020 to November 2022 and were diagnosed with Shoulder Impingement Syndrome (SIS). Thorough histories and clinical exams were done. The Department of Radiology, MKCG Medical College and Hospital, Berhampur, performed conventional shoulder MRIs on the selected participants.

Results: Most cases and controls were Type-II (43.3%), followed by Type-I (28.3% and 30%, 29.2% of the total group). The study's least common acromial shape was type-IV, seen in 5% of cases and 10% of controls (7.5% of the sample). Fisher's exact test showed no significant connection between subacromial impingement and acromial shape ($p=0.65$). With a p -value of 0.045, cases had a significantly greater acromial width (8.12 ± 2.16 mm) than controls (7.51 ± 0.81 mm).

Conclusion: Sub-acromial impingement was unrelated to acromion morphology. There was no correlation between acromial morphology and rotator cuff injuries.

Key-words: Shoulder Impingement Syndrome, Acromion Morphology, MRI

INTRODUCTION

A painful shoulder is the third most encountered musculoskeletal complaint in day-to-day orthopaedic clinical practice that can lead to considerable morbidity^[1].

Its prevalence ranges between 7% and 27% in the general population, as reported^[2,3]. It is even more frequent among athletes who regularly perform overhead arm activity, which can be as high as 36 to 66%^[4-6]. Considering the pathophysiology, its causes can be numerous: functional, degenerative, and mechanical.

The most common diagnosis of shoulder pain is subacromial pain syndrome (SAPS)^[7], routinely referred to as ‘shoulder impingement syndrome’ (SIS)^[8]. The impingement hypothesis supposes a

How to cite this article

Dash A, Pradhan CS, Patro GC, Das J. Assessment of Acromion Morphology in Association with Shoulder Impingement Syndrome using MRI. SSR Inst. Int. J. Life Sci., 2023; 9(6): 3428-3438.



Access this article online

<http://ijls.com/>

pathophysiological mechanism in which there is mechanical conflict among the various structures of the shoulder joint. Out of all types of shoulder pain, the prevalence of SAPS is 36 to 48% [7,9].

SAPS is a clinical syndrome with painful entrapment of specific soft tissues in an area of the shoulder joint. Patients affected are generally over 40 years of age, suffering from chronic pain without any known history of preceding trauma. SIS is most commonly diagnosed in the sixth decade [2,7-11]. This syndrome usually causes pain on elevating the arm, thus limiting the shoulder range of motion [12,13]. Patients complain of pain on elevating the arm between 70° and 120° (the “painful arc”), on attempting forced movement above the head, and also while lying on the affected side [14].

This syndrome, if left untreated, could result in rotator cuff disruption which then persists to cause secondary osteoarthritis of the shoulder, severely restricting shoulder movement in the end [12].

The pathophysiologic cause of shoulder impingement syndrome is multifactorial, and the relative importance of each component remains debated. Nowadays, the mechanisms contributing to rotator cuff disease are mainly classified into intrinsic and extrinsic factors. The intrinsic factors include abnormalities within the rotator cuff itself: alteration in the collagen fibre microstructure, tensile overload, aging, decrease in microvascular supply, and traumatism, which usually results in degeneration of the tendon itself [15]. The extrinsic factors are mainly some anatomic variables such as acromial morphology or abnormal scapular biomechanics, acromial spurs, morphology of the coracoacromial ligament and acromioclavicular joint, which would narrow the subacromial space and increase pressure on tendons by impingement from bony structures or surrounding soft tissues [15,16]. There still exist debates on which mechanism is primary or secondary, but in most patients, it seems to be an interaction between both.

Some have suggested that extrinsic osseous impingement is the primary etiologic mechanism of rotator cuff disease and that osseous impingement is related to several causes, such as acquired and often degenerative bone production, congenital and developmental variants in bone shape and os

acromiale [17-20]. Osteophytes, hypertrophic changes, and bony spurs in the acromion have been considered major extrinsic causes of SIS. Subacromial or acromioclavicular spurs were reported in almost half of SIS cases [21].

In some cases, the symptoms are relieved by conservative treatment alone. However, some patients with specific structural pathology, such as bone spur of acromion or compression of acromial undersurface, might require surgical procedures, such as acromioplasty, for definitive treatment [2,17,22-24]. Subacromial decompression and acromioplasty are regular surgical methods performed over a long period to treat SIS. However, it is still controversial as to precisely which part of the acromion needs to be resected or decompressed.

A significant component of osseous impingement is the morphologic characteristics of the acromion. Consequently, numerous attempts have been made to grade acromial morphologic features. The most notable is the flat (type I), curved (type II), and hooked (type III) classification by Bigliani and colleagues [25], who originally described the acromion by using anatomic specimens. This classification has subsequently been applied to acromia by using multiple imaging modalities. All analyses have been subjective to variable degrees, and significant intraobserver and interobserver variability has been demonstrated [26-28].

The pathogenesis of SIS seems to be related to the morphology of the acromion, which is usually assessed through the commonly used parameters on standard plain radiographs including the acromial type, acromial slope, acromial tilt, lateral acromial angle, critical shoulder angle, acromial index, acromiohumeral distance, etc [29]. However, with only a plain radiograph of the acromion in the supraspinatus outlet view, it is notoriously difficult to image the acromion and distinguish the hooked from the non-hooked acromion with anterior spurs [30,31].

Magnetic resonance imaging (MRI) makes it possible to depict the shape of acromion in its longitudinal axis with better evaluation of these acromial morphological factors, which have been suggested to influence the rotator cuff status [32,33].

This study aims to identify the morphological characteristics of the acromion associated with SIS using MRI and recognize the relationship between type of the acromion and the occurrence of SIS to aid in better treatment of SIS.

MATERIALS AND METHODS

This observational study was made in the Department of Orthopaedics, MKCG Medical College and Hospital, Berhampur, among a section of Eastern Indian Population attending the outpatient department of MKCG Medical College and Hospital, India.

Adult subjects (between 18-75 years) of both sexes who presented to the OPD of MKCG Medical College and Hospital from December 2020 to November 2022 with complaints of shoulder pain who were then diagnosed to have Shoulder Impingement Syndrome (SIS) were considered for the study. Detailed histories were taken and thorough clinical examinations were performed. Conventional MRI of the shoulder joints of the selected subjects were done in the Department of Radiology, MKCG Medical College and Hospital, Berhampur, India.

A total of 60 patients from among these who had signs and symptoms consistent with the clinical diagnosis of unilateral subacromial impingement with or without RCT were enrolled in the impingement (SIS) group.

Inclusion criteria for the SIS group

- Shoulder pain during active arm elevation
- A painful arc (70°-120°)
- Weakness or pain with resisting scapular plane abduction on internal humeral rotation or resisting isometric external rotation,
- Positive Hawkins–Kennedy test: pain on maximal internal rotation of the arm in 90° of anteversion with the elbow flexed
- Positive Neer impingement sign: pain at passive elevation and internal rotation
- Positive Neer impingement test: pain relieved after injection of local anaesthetic into the subacromial space.

Exclusion criteria for the SIS group

- Evidence of glenohumeral osteoarthritis
- Previous fracture or dislocation involving the humerus, clavicle or scapula

- Previous surgery around shoulder joint
- Previous shoulder injury as a result of trauma
- Congenital deformities around the shoulder joint
- Infections in and around the shoulder joint
- Tumours involving the shoulder joint
- Pregnant women
- Patients with any metallic implants unsuitable for MRI
- Patients refusing to be included in the study.

A control group was also enrolled comprising of 60 individuals, who had presented with complaints of shoulder pain and underwent MRI for the same but were diagnosed as having calcifying tendinitis or frozen shoulder without any evidence of impingement or partial/complete rotator cuff tear and meeting the exclusion above criteria.

General information like name, age, sex, and address was recorded. A history of present complaints was taken regarding pain in the shoulder on abducting the arm between 70° and 120° (the “painful arc”), on forced overhead movement, or while lying on the affected side. Relevant past and family history was taken. The above-mentioned clinical tests were performed.

All MRI images of the study were performed by using 1.5- Tesla Cura Magnetom unit system available at the Department of Radiodiagnosis of MKCGMCH. All measurements were taken by annotation tools from a soft copy of the MRI using Centricity DICOM Viewer Software and the parameters were tabulated. A dedicated shoulder array coil was used. When imaging the shoulder with MRI, patients were placed supine with their arms on the sides of the body in partial external rotation. Initially, the localizer images were obtained, followed by coronal oblique, sagittal oblique, and axial images. The coronal oblique plane was selected parallel to the course of the supraspinatus for optimal tendon visualisation. Types of the acromion were evaluated in the T2 weighted (T2WI) sagittal oblique images. This sagittal oblique plane was parallel to the glenoid surface, with a selection of the images obtained just lateral to the acromioclavicular joint. Acromial morphology was classified into four types: type-I (flat), type-II (curved), and type-III (hooked) and type-IV (convex or upturned), tabulated as a qualitative variable.

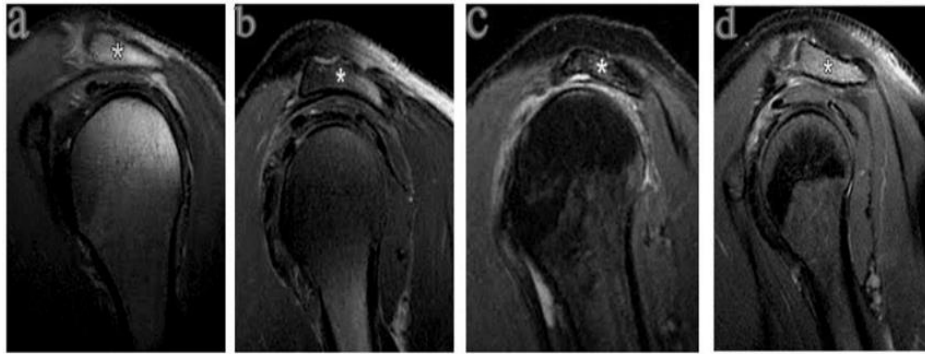


Fig. 1: Classification of Acromial Morphology as evidenced by MRI (T2WI);
a (flat), b (curved), c (hooked), d (convex)

The obtained images were retrieved from our institutional picture archiving and communication system (PACS) and assessment of the acromial type at parasagittal MR images was achieved mathematically by using the mathematical classification scheme for MR images, where a line connecting the most caudal margins of the acromial undersurface was manually drawn and its length was measured. This line was then divided into three segments of equal lengths with the help of two orthogonal lines.

Then, the angle between the anterior third and the posterior two-thirds of the acromion was measured. If this angle was 10° or less, type I acromion was considered. Type II acromion was recognized, if it was between 11° and 20° . If this angle was more than 20° , the angle between the posterior third and the anterior two-thirds was further measured. If this latter angle was 10° or less, type III acromion was

defined and if more than 10° this would be type IV acromial shape.

Statistical Analysis- The resultant data was analysed using Statistical Package for Social Sciences, version 26.0 (SPSS® Inc. Chicago, IL USA). For all analyses, p -value < 0.05 was set to be significant.

RESULTS

Among the 120 study participants, 59 (49.2%) were male and 61 (50.8%) were females. A nearly equal number of males and females presented in each group. The chi-square test was used to determine the significance of results regarding sex distribution among the two groups. It yielded p -value of 0.85, which implies no significant difference in the distribution of sexes between the two groups (Table 1 & 2).

Table 1: Sex distribution between cases and controls

	Impingement (%)	Control (%)	Total (%)	p- value
		Sex		0.855
Male	29 (48.3)	30 (50)	59 (49.2)	29 (48.3)
Female	31 (51.7)	30 (50)	61 (50.8)	31 (51.7)
Total	60 (100)	60 (100)	120 (100)	

Table 2: Age distribution between cases and controls

Age group (years)	Impingement (%)	Control (%)	Total (%)
18-25	0 (0)	0 (0)	0 (0)
26-35	0 (0)	0 (0)	0 (0)
36-45	7 (11.67)	2 (3.33)	9 (7.50)
46-55	16 (26.67)	16 (26.67)	32 (26.67)

56-65	15 (25.00)	23 (38.33)	38 (31.67)
66-75	22 (36.67)	19 (31.67)	41 (34.17)
Total	60 (100)	60 (100)	120 (100)

The mean age of the study participants was 58.82 (± 10.28) years. With a median age of 62, the participants ranged from 37 to 75 years. The majority of the participants were over 65 years (34.17%), followed by 56-65 years (31.67%). There were no participants aged below 35 years in the study. The age distribution of

participants between the two groups is illustrated below. There was no significant statistical difference between the two groups in age distribution, with a p-value of 0.197 resulting from the Chi-square test between the groups (Table 3).

Table 3: Distribution of acromion shape among cases and controls

	Impingement (%) (N=60)	Control (%) (N=60)	Total (%) (N=120)	p-value
Acromion shape				
Type-I	17 (28.3)	18 (30)	35 (29.2)	0.65
Type-II	26 (43.3)	26 (43.3)	52 (43.3)	
Type-III	14 (23.3)	10 (16.7)	24 (20.0)	
Type-IV	3 (5.0)	6 (10)	9 (7.5)	

The most prevalent type, among both cases and controls, was found to be Type-II, constituting 43.3% of both cases and controls, followed by Type-I, constituting 28.3% of cases and 30% of controls (29.2% of the total sample). Type-IV was the least common acromial shape encountered in the study, comprising only 5% of the

cases and 10% of the controls (7.5% of the total sample). Analysis using the Fisher exact test yielded p-value of 0.65, implying no significant relationship between subacromial impingement and acromial shape was found in this study (Table 4).

Table 4: Distribution of acromion shape in patients with SIS with respect to sex

	Type-I (%) (N=35)	Type-II (%) (N=52)	Type-III (%) (N=24)	Type-IV (%) (N=9)	Total (%) (N=120)	p-value
Sex						
Female	18 (51.4)	26 (50)	12 (50)	5 (55.6)	61 (50.8)	1
Male	17 (48.6)	26 (50)	12 (50)	4 (44.4)	59 (49.2)	

The distribution of acromion shape among patients of SIS concerning sex was analysed using Chi-square test, which yielded a p-value of 1, implying no significant relationship was observed between the sex of the

patient and acromial shape. The age distribution of acromion shapes in patients of SIS was also analysed using Chi-square test and with a p-value of 0.91, it was found to be insignificant (Table 5).

Table 5: Distribution of acromion shape in patients with SIS for age

	Type-I	Type-II	Type-III	Type-IV	Total	p-value
	Age groups					
18-25	0	0	0	0	0	0.91
26-35	0	0	0	0	0	
36-45	3	2	2	0	7	
46-55	3	8	4	1	16	
56-65	4	7	4	0	15	
66-75	7	9	4	2	22	

Acromial width (AW) of cases (8.12 ± 2.16 mm) was significantly higher than controls (7.51 ± 0.81 mm), with a p-value of 0.04. However, the AW was not significantly different among the four acromial types ($p=0.13$). Acromial tilt (AT) of cases ($26.18 \pm 3.72^\circ$) was significantly lower than controls ($28.27 \pm 3.92^\circ$) with p-value of 0.01. Also, among cases of SIS, AT of type-II ($25.69 \pm 3.30^\circ$) and type-III ($24.97 \pm 3.35^\circ$) were significantly lower than the control group, with p-values of 0.03 and 0.03, respectively. Modified acromial tilt (mAT) of cases ($19.18 \pm 3.07^\circ$) was also significantly lower than controls ($21.27 \pm 3.68^\circ$) with p-value < 0.001 . Also, among cases of SIS, mAT of type-II ($18.68 \pm 2.59^\circ$) and type-III ($18.47 \pm 3.36^\circ$) were significantly lower than the control group

with p-values of 0.012 and 0.047.

Acromio-humeral distance (AHD) of cases (7.85 ± 1.77 mm) was also significantly lower than controls (8.64 ± 2.28 mm) with p-value of 0.03. However, there was no significant variation in the AHD among the four acromial types ($p=0.27$). Acromial index (AI) of cases (0.62 ± 0.14) was higher than controls (0.59 ± 0.10). However, the difference was not significant, with p-value of 0.13. Also, there was no significant variation in the AI among the four acromial types ($p=0.66$). Lateral acromial angle (LAA) of cases ($74.90 \pm 4.55^\circ$) was found to be lower than controls ($76.31 \pm 5.08^\circ$). However, the difference was not significant, with p-value of 0.11. Also, there was no significant variation in the LAA among the four acromial types ($p=0.17$) (Tables 6 & 7).

Table 6: Variations of nine quantitative acromial morphological parameters among the four different Bigliani acromial types

	Control (N=60)	Type-I (N=17)	Type-II (N=26)	Type-III (N=14)	Type-IV (N=3)	Total (N=120)	p-value
AW (mm)	7.51 (0.81)	7.72 (2.41)	8.06 (2.06)	8.75 (1.95)	7.91 (3.14)	7.81 (1.65)	0.08
Mean (SD) Range	5.46-9.55	3.47-11.32	4.08-11.52	4.16-10.81	4.67-10.95	3.47-11.52	
AT ($^\circ$)	28.27 (3.92)	27.71 (4.38)	25.69 (3.30)	24.97 (3.35)	27.42 (3.10)	27.23 (3.95)	0.09
Mean (SD) Range	18.87-35.87	18.48-34.94	18.31-31.42	16.12-29.02	23.99-30	16.12-35.87	
MAT ($^\circ$)	21.27 (3.68)	20.41 (3.32)	18.68 (2.59)	18.47 (3.36)	19.81 (3.47)	20.23 (3.54)	0.08
Mean (SD) Range	12.76-27.58	13.45-25.48	11.85-22.85	11.30-22.57	16.88-23.65	11.30-27.58	
AHD (mm)	8.64 (2.28)	8.02 (2.00)	7.96 (1.44)	7.40 (2.12)	7.97 (1.92)	8.24 (2.07)	0.07
Mean (SD) Range	3.84-13.18	4.16-11.88	5.71-10.33	4.16-11.78	6.02-9.86	3.84-13.18	

AI	0.59 (0.10)	0.61 (0.16)	0.62 (0.15)	0.63 (0.11)	0.60 (0.05)	0.60 (0.12)	0.08
Mean (SD)	0.32-0.80	0.19-0.77	0.39-0.95	0.44-0.79	0.56-0.65	0.19-0.95	
Range							
LAA (°)	76.31 (5.08)	75.45 (4.90)	75.45 (3.94)	72.68 (4.82)	75.50 (5.34)	75.61 (4.85)	0.07
Mean (SD)	61.67-88.96	68.79-81.48	68.79-81.48	66.10-81.88	69.34-78.78	61.67-88.96	
Range							
CSA (°)	28.12 (4.19)	29.37 (4.73)	29.76 (3.95)	32.49 (5.22)	28.81 (5.04)	29.18 (4.51)	0.45
Mean (SD)	18.93-39.49	23.26-38.59	23.26-38.59	20.99-39.13	24.12-34.14	18.93-39.49	
Range							
AIP (mm)	3.92 (2.22)	4.94(2.88)	5.63 (2.84)	6.37 (2.83)	3.82 (2.69)	4.72 (2.66)	0.36
Mean (SD)	0.68-8.18	0.85-9.15	0.80-12.89	2.61-10.86	2.08-6.92	0.68-12.89	
Range							

Table 7: Analysis of variance among the four acromial types vs control

Parameters	Control			
	Type-I vs	Type-II vs	Type-III vs	Type-IV vs
AW	0.98	0.61	0.08	0.99
AT	0.98	0.03	0.03	0.99
mAT	0.88	0.01	0.04	0.95
AHD	0.81	0.62	0.26	0.98
AI	0.91	0.75	0.78	0.99
LAA	0.99	0.94	0.08	0.99
CSA	0.83	0.49	0.01	0.99
AIP	0.58	0.03	0.01	0.99
AAP	0.70	0.08	0.04	0.99

Critical shoulder angle (CSA) of cases ($30.24 \pm 4.60^\circ$) was found to be significantly higher than controls ($28.12 \pm 4.19^\circ$) with p-value 0.01. Also, among cases of SIS, type- III ($18.68 \pm 2.59^\circ$) had significantly higher CSA than controls with p-value 0.01. Acromial inferior protrusion (AIP) of cases (5.52 ± 2.85 mm) was significantly higher than controls (3.92 ± 2.22 mm) with p-value < 0.001. Also, among cases of SIS, AIP of type-II (5.63 ± 2.84 mm) and type-III (6.37 ± 2.83 mm) were significantly higher than the control group, with p-values 0.03 and 0.01, respectively

(Table 7).

Acromial anterior protrusion (AAP) of cases (7.27 ± 2.65 mm) was also significantly higher than controls (5.79 ± 2.54 mm), with a p-value of 0.002. Also, among cases of SIS, AAP of type-III (7.97 ± 2.94 mm) was significantly higher than controls with p-value of 0.04 (Table 7). Only 13 out of 60 cases of impingement had rotator cuff tear (RCT) on MRI. They were identified as partial or complete, tabulated and analyzed (Table 8).

Table 8: Distribution of rotator cuff tears among different acromial types

Acromion shape	Full thickness (%) (N=6)	Partial thickness (%) (N=7)	Total (%) (N=13)
Type-I	1 (16.7)	2 (28.6)	3 (23.1)
Type-II	1 (16.7)	3 (42.9)	4 (30.8)
Type-III	4 (66.7)	2 (28.6)	6 (46.2)
Type-IV	0 (0)	0 (0)	0 (0.0)

DISCUSSION

This study was therefore designed to analyse the morphologic characteristics of different acromia in patients with subacromial impingement with or without partial or complete thickness RCT by using MRI as the diagnostic modality of choice to elucidate the relationship between acromial shapes and SIS clearly, which could, in turn, prove a helpful guide in the diagnosis and management of impingement and rotator cuff tendinopathy.

Similar to previous studies^[34], the current study also observed that type-II acromial shape is the most commonly encountered type among patients and control groups (43.33% in both groups). Conversely, type-IV acromion shape was the least prevalent among case and control groups (5% and 10%, respectively). In both groups, there was no significant demographic difference ($p>0.05$) in age and sex regarding the occurrence of impingement.

This is contrary to a previous study by Paraskevas *et al.* [34], which noted that type-I acromion was significantly more common in females (13 or 56.5% vs. 10 or 43.4%). In contrast, type-III was significantly more common in males (9 or 56.2% vs. 7 or 43.7% in females). The present study noted almost equal sex distribution among all four acromion types. With p -value of 0.65 using the Fisher exact test, the present study found no statistically significant relationship between acromion shape and subacromial impingement. In this study, the acromial morphometric differences between impingement and control patients indicate significant anterior and inferior prominence of the impinged acromia. These results were consistent with previous reports^[35].

Nevertheless, this data could only support the correlation, but not the causal relationship between subacromial impingement and acromion morphology.

Previously, a side-to-side comparison by Li *et al.*^[36] in 2017 demonstrated significant morphological differences between the affected and non-affected shoulders on CT imaging in patients of SIS. On the other hand, the differences were negligible in controls. These findings in this previous study may provide added credibility to the intrinsic factor theory in the development of subacromial impingement: initially, rotator cuff tendon degeneration occurs, further leading to unbalanced force couples around the shoulder with resultant antero-superior glenohumeral instability; subsequently, as a mechanism of compensation and to restrict this instability, bone spurs gradually grow along the coracoacromial arch, creating a deformed acromion. In this case, it is quite rational to expect a morphological difference between the affected and non-affected acromia in impingement patients.

In the present study, it was impossible to compare side-to-side with the unaffected normal shoulder of the impingement patients due to cost and time constraints. Hence, the conclusions of the previous study by Li *et al.*^[36], though they could not be verified, must be borne in mind while evaluating the cause and planning out optimal treatment in patients with subacromial impingement. The mean acromial width (AW) in patients with impingement (8.12 mm) was significantly thicker than in the control group (7.51 mm), with a p -value of 0.04. This is by the conclusion of previous studies^[37]. The AW of Type-III (8.75 mm), though markedly thicker than the other three types and

the control, was statistically insignificant. Therefore, revealed significant inferior protrusion of impinged acromia, with significantly lower AT, mAT and significantly higher AIP. These findings agree with the previous CT-based study by Li *et al.* [36]

In this study, the impingement group (7.27 mm) exhibited significantly higher AAP than the control group (5.79 mm), with a p-value of 0.01, implying significant anterior prominence of the impinged acromia. The study also reveals significantly higher AAP of type-III acromia (7.97 mm), compared with other types and controls. These findings align with Li *et al.* [36]. The present study reveals significantly lower AHD among impinged acromia (7.85 mm) than controls (8.64 mm) with a p-value of 0.03. However, no significant variation was found in the AHD among the four acromial types in SIS patients. These findings align with previous studies [38] and signify the presence of marked superior migration of the humeral head in impinged acromia independent of the acromial shape.

In the present study, the AI of impinged acromia (0.62) was higher than controls (0.59), signifying a more excellent coverage of the subacromial tissues by the acromion. However, this difference in AI between cases and controls was non-significant ($p=0.13$), nor did it display any significant variation among the four acromial types. This is in line with the previous similar study conducted by Li *et al.* [36]. In this study, the LAA of impinged acromia (74.90°), though relatively lesser than controls (76.31°) again, the difference was found to be statistically insignificant ($p=0.11$), neither was there any significant difference in LAA among the four acromial types. However, type-III acromia (72.68°) displayed a trend towards lower LAA compared with the other types.

The present study tries to establish the relationship between CSA and subacromial impingement. The CSA of impinged acromia (30.24°) was significantly greater than controls (28.12°) with a p-value of 0.01, implying increased acromial cover laterally over the glenoid. This finding aligns with Li *et al.* [36]. Among the cases, type-III acromia (32.49°) demonstrated significantly higher CSA than other acromial types and controls.

CONCLUSIONS

There was non-significant relationship between acromion shape and subacromial impingement. There was no significant association established between acromial shape and rotator cuff tears. Compared to controls, the impinged acromia are significantly thicker (higher AW), more prominent inferiorly (lower AT, mAT, & higher AIP) and anteriorly (higher AAP), with increased lateral acromial cover over the glenoid (greater CSA), superior migration of the humeral head (lesser AHD) and narrowing of the subacromial space. This study, therefore, concludes that shoulder impingement is associated with significant acromial morphological variations.

Genetic factors influencing acromial differences and personalized therapeutic strategies could be the subject of future research. Understanding the causes of SIS can potentially improve patient outcomes by implementing more effective treatments and safeguards in the future. Beyond aiding in the diagnostic process, this study paves the way for improved clinical practices and a broader comprehension of shoulder-related conditions.

ACKNOWLEDGMENTS

The authors are highly grateful to the respective Universities and Principals of relevant Institutions to carry out the present investigations.

CONTRIBUTION OF AUTHORS

Research concept- Abhisek Dash

Research design- Chandra Sekhar Pradhan

Supervision- Gopal Chandra Patro

Materials- Abhisek Dash

Data collection- Abhisek Dash

Data analysis and Interpretation- Abhisek Dash

Literature search- Gopal Chandra Patro

Writing article- Chandra Sekhar Pradhan

Critical review- Gopal Chandra Patro

Article editing- Jyotibhanja Das

Final approval- Gopal Chandra Patro

REFERENCES

- [1] Urwin M, Symmons D, Allison T, et al. Estimating the burden of musculoskeletal disorders in the community: the comparative prevalence of symptoms at different anatomical sites, and the relation to social deprivation. *Ann Rheum Dis.*,

- 1998; 57: 649–55.
- [2] Garving C, Jakob S, Bauer I, Nadjar R, et al. Impingement syndrome of the shoulder. *Dtsch Arztebl Int.*, 2017; 114: 765-76.
- [3] De-Yang TJ, Tan AHC. Shoulder impingement syndrome, a common affliction of the shoulder: a comprehensive review. *Proc Singapore Healthc.*, 2014; 23: 297-305.
- [4] Myklebust G, Hasslan L, Bahr R, Steffen K. High prevalence of shoulder pain among elite Norwegian female handball players. *Scand. J Med Sci Sports*, 2013; 23: 288–94.
- [5] Oliveira, Mod V, et al. Shoulder pain in adolescent athletes: prevalence, associated factors and its influence on upper limb function. *Braz J Phys Ther.*, 2017; 21: 107–13.
- [6] Rodeo SA, Nguyen JT, Cavanaugh JT, Patel Y, Adler RS. Clinical and ultrasonographic evaluations of the shoulders of elite swimmers. *Am J Sports Med.*, 2016; 44: 3214–21.
- [7] Juel NG, Natvig B. Shoulder diagnoses in secondary care, a one year cohort. *BMC Musculoskelet Disord.*, 2014; 15: 89.
- [8] Neer CS, Welsh RP. The shoulder in sports. *Orthop Clin North Am.*, 1997; 8: 583–91.
- [9] Van der Windt DA, Koes BW, de Jong, BA, Bouter LM. Shoulder disorders in general practice: incidence, patient characteristics, and management. *Ann Rheum Dis.*, 1995; 54: 959–64.
- [10] Makela M, Heliövaara M, Sainio P, Knekt P, Impivaara O, et al. Shoulder joint impairment among Finns aged 30 years or over: prevalence, risk factors and co- morbidity. *Rheumatol.*, 1999; 38: 656–62.
- [11] Yamaguchi K, Ditsios K, Middleton WD, Hildebolt CF, Galatz LM, et al. The demographic and morphological features of rotator cuff disease. A comparison of asymptomatic and symptomatic shoulders. *J Bone Joint Surg Am.*, 2006; 88: 1699–704.
- [12] Blom AW, Warwick D, Whitehouse MR. *Apley and Solomon's system of orthopaedics and trauma*. 10th ed Boca Raton: Taylor & Francis, 2018.
- [13] Lazaro R. Shoulder impingement syndromes: implications on physical therapy examination and intervention. *J Jpn Phys Ther Assoc.*, 2005; 8: 1-7.
- [14] Habermeyer P. *Schulterchirurgie*. Munchen: Elsevier, Urban & Fischer 2010; 4th edition.
- [15] Almekinders LC, Weinhold PS, Maffulli N. Compression etiology in tendinopathy. *Clin Sports Med.*, 2003; 22: 703–10.
- [16] Matthews TJ, Hand GC, Rees JL, Athanasou NA, et al. Pathology of the torn rotator cuff tendon. Reduction in potential for repair as tear size increases. *J Bone Joint Surg Br.*, 2006; 88: 489–495.
- [17] Neer CS II. Anterior acromioplasty for the chronic impingement syndrome in the shoulder: a preliminary report. *J Bone Joint Surg Am.*, 1992; 54: 41–50.
- [18] Yazici M, Kopuz C, Gulman B. Morphologic variants of acromion in neonatal cadavers. *J Pediatr Orthop.*, 1995; 15: 644–47.
- [19] Nicholson GP, Goodman DA, Flatow EL, Bigliani LU. The acromion: morphologic condition and age-related changes-a study of 420 scapulas. *J Shoulder Elbow Surg.*, 1996; 5: 1–11.
- [20] Hutchinson MR, et al. Arthroscopic decompression of shoulder impingement secondary to os acromiale. *Arthroscopy*, 1993; 9: 28–32.
- [21] Seeger LL, Gold RH, Bassett LW, Ellman H. Shoulder impingement syndrome: MR findings in 53 shoulders. *AJR Am J Roentgenol.*, 1998; 150: 343-47.
- [22] Dhillon KS. Subacromial impingement syndrome of the shoulder: a musculoskeletal disorder or a medical myth? *Malays Orthop J.*, 2019; 13: 1-7.
- [23] Edwards SL, Bell JE, Bigliani LU. Subacromial impingement. In: Wilk KE, Reinold MM, Andrews JR, editors. *The Athlete's Shoulder*. 2nd ed. Philadelphia: Churchill Livingstone, 2009; pp. 115-22.
- [24] Morrison DS, Frogameni AD, Woodworth P. Non-operative treatment of subacromial impingement syndrome. *J Bone Joint Surg Am.*, 1997; 79: 732-37.
- [25] Bigliani LU, Morrison DS, et al. The morphology of the acromion and its relationship to rotator cuff tears. *Orthop Trans.*, 1996; 10: 216.
- [26] Zuckerman JD, Kummer FJ, Cuomo F, Greller M. Interobserver reliability of acromial morphology classification: an anatomic study. *J Shoulder Elbow Surg.*, 1997; 6: 286–87.

- [27] Jacobson SR, Speer KP, Moor JT, et al. Reliability of radiographic assessment of acromial morphology. *J Shoulder Elbow Surg.*, 1995; 4: 449–53.
- [28] Peh WC, Farmer TH, Totty WG. Acromial arch shape: assessment with MR imaging. *Radiol.*, 1995; 195: 501–05.
- [29] Balke M, Schmidt C, Dedy N, et al. Correlation of acromial morphology with impingement syndrome and rotator cuff tears. *Acta Orthopaedica.*, 2013; 84(2): 178–83.
- [30] Bigliani LU, Morrison DS, Ticker JB, et al. Relationship of acromial architecture and diseases of the rotator cuff (in German). *Orthopade*, 1991; 20: 302-09.
- [31] Nho SJ, Yadav H, Shindle MK, et al. Rotator cuff degeneration: etiology and pathogenesis. *Am J Sports Med.*, 2008; 36(5): 987–93.
- [32] Morag Y, Jacobson A, Miller B, et al. MR imaging of rotator cuff injury: what the clinician needs to know? *Radio Graphics*, 2006; 26: 1045-65.
- [33] Hirano M, Ide J, Takagi K. Acromial shapes and extension of rotator cuff tears: magnetic resonance imaging evaluation. *J Shoulder Elbow Surg.*, 2002, 576-78.
- [34] Paraskevas G, Tzaveas A, Papaziogas B, et al. Morphological parameters of the acromion. *Folia Morphol.*, 2008; 67(4): 255–60.
- [35] Nagerl H, Kubein-Meesenburg D, Cotta H, Fanghanel J, Kirsch S: Biomechanical principles in diarthroses and synarthroses. II: The humerus articulation as a ball-and- socket joint. *Z Orthop Ihre Grenzgeb.*, 1993; 131: 293–301.
- [36] Li X, Xu W, Hu N, Liang X, Huang W, et al. Relationship between acromial morphological variation and subacromial impingement: a three-dimensional analysis. *PLoS One*, 2017; 12: e0176193.
- [37] Habermeyer PS. München: Elsevier, Urban & Fischer 2010; 4th edition.
- [38] Harrison AK, Flatow EL: Subacromial impingement syndrome. *J Am Acad Orthop Surg.*, 2011; 19: 701–08.

Open Access Policy:

Authors/Contributors are responsible for originality, contents, correct references, and ethical issues. SSR-IJLS publishes all articles under Creative Commons Attribution- Non-Commercial 4.0 International License (CC BY-NC). <https://creativecommons.org/licenses/by-nc/4.0/legalcode>

