

Morphological Changes of Placenta Associated with Maternal Anaemia

Gopal Chandra Mondal¹, Anupam Baske^{2*}, Sharmistha Biswas³

¹Associate Professor, Department of Anatomy, N.R.S. Medical College, Kolkata, India

²Demonstrator, Department of Anatomy, B. S. Medical College, Bankura, West Bengal, India

³Professor, Department of Anatomy, Malda Medical College, Malda, West Bengal, India

*Address for Correspondence: Dr. Anupam Baske, Demonstrator, Department of Anatomy, B. S. Medical College, Kolkata B J 145, Sector 2, Salt Lake, Kolkata 700091, India

Received: 11 June 2017/Revised: 20 July 2017/Accepted: 30 August 2017

ABSTRACT- Placenta is the mirror of fetomaternal status. The effect of anemia in pregnancy can be diverse and detrimental to the mother and the fetus. This prompted us to carry out the present study, which aimed to observe and compare the morphological features of placenta at term in anemic and non-anemic mothers of North Bengal and to find out the clinical relevance of such structural changes.

Total 30 placentas were collected from each group of selected patients after delivery at labor room. Examination of placenta was conducted according to proforma. A general survey of umbilical cord, membranes, fetal surface, and maternal surface was carried out. The diameters were measured, area was estimated, and shape was noted. Placenta and fetus was weighed in the same scale. The volume was estimated by water displacement method.

In anemic mothers, mean baby birth weight was found to be significantly less than that of control group. The mean placental weight in the test group was significantly increased in comparison to controls. The mean placental volume and mean placental area in case of test group were significantly increased. Occurrence of morphological features, like subchorionic fibrosis; retroplacental clot, gross calcification, or placental infarction etc were found to be significantly higher in anemic mothers in comparison to non-anemic group.

In the present study, it was proved that placenta has the considerable functional reserve capacity. It tends to limit the ill-effects of tissue injury and of unfavorable maternal milieu like anemia. Our findings were in accordance with the previous studies in this field.

Key-words- Placenta, Maternal anaemia, Morphological changes, Placental weight

INTRODUCTION

Placenta is the most accurate record of the infants' prenatal experience ^[1]. It is the vital organ for maintaining pregnancy and promoting normal fetal development. The human placenta is a flattened discoid organ, which connects the fetus with the uterine wall. It has a maternal component, decidua basalis and a fetal component, chorion frondosum. The fetus and the placenta share the same genetic makeup and so therefore both should be expected to possess parallel growth potentials.

Maturation of placenta causes an increase in the placental nutrient transfer capacity and thus improves placental efficiency, permitting an increase in the number of grams of fetal weight supported by every gram of placental mass. Not surprisingly "Placental insufficiency" is invoked commonly in case of impaired fetal growth ^[2].

At full term the human placenta consists of:

- Fetal surface**, which is smooth, glistening, covered by the amnion and presents the insertion of the umbilical cord close to its centre.
- Maternal surface** rough, irregular consists of 15–30 cotyledons separated by fissures that arise from the folding of the basal plate.
- Umbilical cord** insertion is usually central but may vary in some specimens like battledore/marginal, velamentous, eccentric etc.

At full term, the dimensions are as follows:

Placental weight is approx. 500 gm, diameter: 15–20 cm; thickness: 3 cm; volume: 500 ml. Length of umbilical cord: 50 cm; breadth: 2 cm.

These measurements vary widely; there are several types of human placentas with variant cord insertions, and also shape: rounded in 81.6%, oval in 16%, irregular in 2.4% ^[3-5]. Flattened discoid shape of placenta with an approximately circular outline was described as normal ^[4] as well as in maternal iron-deficiency anaemia ^[6].

Size of placenta can be calculated by measuring its diameter, thickness, area, weight and volume ^[7-8]. Usually, the placenta is 150-200 mm (average 185 mm) in diameter and 10-40mm (average 23mm) in thickness

Access this article online

Quick Response Code	Website: www.ijlssr.com
	 DOI: 10.21276/ijlssr.2017.3.5.23

^[4]. Previously it was observed that presence of low maternal hematocrit was associated with higher placental weight ^[9]. Recent studies suggested an increase in placental weight in anemic mothers ^[10]. There is probably a compensatory physiological hypertrophy of the placenta resulting from inadequate oxygen supply to the fetus ^[11].

Volume of the placenta is proportional to its weight ^[12]. Placental volume is markedly reduced in abnormally small babies ^[13]. Volume of placenta is increased in male babies than females ^[14]. Because of the fact that placenta has a normally unrealized potential for incremental growth ^[9,15-18], certain patho-physiological conditions such as high altitude, severe anemia and maternal heart failure are associated with unusually large placental volume.

Placenta extrachorialis, the commonest developmental variant of the placenta is found in 25% of all placentas. Circumvallate form of placenta extrachorialis, whether partial or complete, is associated with an increased incidence of low birth weight ^[12,19-21], congenital malformation ^[22], prematurity, prenatal bleeding and abruption ^[23].

The normal placenta can contain 8–20 cotyledons ^[24]. Reduced number of cotyledons can be seen in maternal malnutrition, especially in severe anemia ^[25]. Calcification of placenta is a sign of physiological maturity of placenta ^[26]. More mature and heavy the placenta more is the extent of calcified patches ^[27]. Placental calcification occurs earlier in pregnancy in cigarette smokers ^[28].

The placenta was subjected to cystic degeneration also, related to maturation ^[29]. Out of a series of 630 placentas collected from cases of toxemia and diabetes, 40 had cystic changes ^[30]. Placental infarction is described as an area of necrotic changes; extensive infarction is the hallmark of a severe circulatory compromise in placenta ^[31]. Woodling *et al.* ^[32] described “The placental infarct as a consequence of necrosis of maternal cotyledon caused by occlusion of the utero-placental artery those supplies it”. V. Paul Wentworth ^[26] divided infarct into “red infarcts” and “other true infarcts” and also found two similar macroscopic lesions and termed them “perivillous fibrin deposition” and “mottled infarct”. Thrombosis within the tissue is a feature of both normal and abnormal placentas. The clinical significance of such thrombosis is either not known or proved to be none ^[33].

Relevance of present study: Placental change in Anemia

The placenta is the mirror of the fetomaternal status. The effect of anemia in pregnancy can be so diverse and detrimental to both mother and developing fetus that it prompted us to carry on the present study to know whether placenta, an organ acting as a bridge between mother and fetus, is associated with major changes in anemia. Finally, an attempt has been made to confirm, agree or deny the findings of the previous workers in this field.

MATERIALS AND METHODS

The study was conducted during the period of June-2006 to May-2007 in the Department of Anatomy in collaboration with the Department of Pathology and Department of Obstetrics & Gynaecology, North Bengal Medical College & Hospital, Darjeeling, India, which caters for patients from all possible social status. The placentas were collected from booked cases delivered in the Department of Obstetrics & Gynecology. Permission from the ethics committee was taken; informed consent was taken from the patients. Gravid females up to third parity (P₀ to P₃), aged between 17–30 years; height ranging from 148–170 cm and weight ranging from 50–60 kg were taken into consideration.

Routine investigations such as blood grouping, Rh typing, Hemoglobin percentage, Fasting Blood sugar, VDRL, Urine for routine examination was conducted and recorded separately for future references both for test and control groups.

Patients suffering from complications such as hypertension, pre-eclampsia, eclampsia, diabetes, antepartum hemorrhage, heart disease and other gross maternal systemic disorders were excluded.

Control Group (Group I): This group included healthy non-anemic mothers free from significant medical, surgical and obstetrical complications and 30 placentas were collected in this series following live birth only.

Test Group (Group II): This group includes anemic mothers diagnosed clinically and hematologically otherwise free from significant medical, surgical and obstetrical complications and 30 placentas were collected in this series following live birth.

Fresh placentas were collected from the patients selected beforehand. After delivery at labor room, placenta were collected and placed in a bowl for subsequent examination. Examinations of placenta were conducted according to proforma adopted by Benirschke ^[1].

Immediately on collection of placenta, a general survey of umbilical cord, membranes, fetal surface and maternal surface was carried out. Then membranes of placenta were trimmed off by a sharp scissor near the margin as described by Aherne ^[13]. The placentas were subsequently cleansed, free and washed in water.

Following parameters of the placenta were determined:

(a) Dimensions: The maximum & the minimum diameters were measured by the measuring tape. Thickness of each placenta was measured at its centre & three other places by piercing the placenta by a long needle calibrated in cm. The average thickness of the placenta was measured to the nearest 0.1 cm.

(b) Area: The area of placenta was estimated in sq. cm using the formula for the area of an ellipse. Therefore

$$\text{Placental area (cm.}^2\text{)} = \pi \times \text{Max Diameter (cm.)}/2 \times \text{Min diameter (cm.)}/2$$

(c) Weight: It was weighed in the same scale used to measure fetal weight

(d) Volume: Estimated by the water displacement method. A four-liter graduated cylindrical plastic bucket was taken. Two liter of water was taken in the bucket. Volume of water displaced following immersion of placenta into water was measured.

(e) Shape: Shape was noted; whether it was round or oval or any other type.

The Fetal surface was examined by placing the placenta flat on the table with fetal surface upwards (Fig. 1). Then following features were noted:

(a) Insertion of the umbilical cord: Whether it is eccentric, central, battle door or velamentous insertion.

(b) Insertion of membranes: Whether the insertion of membranes on the placenta was marginal or circumvallate was noted.

(c) Amnion: Amnion was examined for its color & translucency.

(d) Amnion nodosum: Presence or absence was noted.

(e) Cyst: Each placenta was examined carefully for presence of cyst. Cyst above the diameter of 0.5 cm was taken into account.

(f) Sub-chorionic fibrosis: Placentas were examined for presence or absence of Sub-chorionic fibrosis and finding were noted accordingly.

(g) Calcification: Sites of calcification, a common feature of placenta were also ascertained and noted.

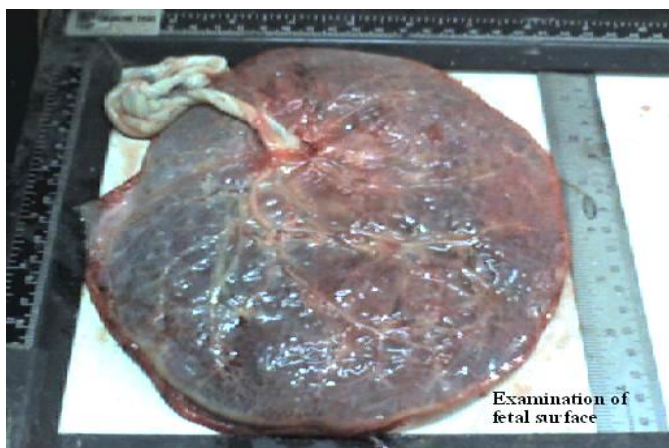

Fig. 1: Examination of Fetal Surface

The surface of the placenta was examined by placing it on the table with the maternal surface directed upwards (Fig. 2) to note whether it is complete or incomplete. The color of maternal surface also noted. In addition, following features were examined:

a) Blood clot: Evidence of any blood clot if present; the size of the same was measured & noted.

b) Calcification: By direct visual assessment presence or absence of calcification was noted.

c) Infarcts: thorough search was made for any macroscopic infarcts.

d) Number of cotyledons in the maternal surface was counted.



Fig. 2: Examination of Maternal Surface

RESULTS

In the present study, the placentas were studied in two groups:

Group I: Control (Non-anemic) group: Included 30 placentas, 50% of the total cases were studied in this series. There were ten primigravida, eleven second gravid, and nine third gravida. The investigation reports/findings of all the cases were absolutely normal. Only 4 cases had the minor obstetric history, i.e. previous MTP.

Blood hemoglobin levels were ranging from 11 gm% to 14 gm% for all the cases of this group.

The mean birth weight of baby in Group I was found to be 2.589 kg, which was heavier in males (2.602 kg) than female (2.572 kg). Placental morphometric values showed almost comparable results in both sexes; except for weight and volume, which were more in male than in female (Table 1). The average numbers of cotyledons were 17.

Group II: Test (Anemic) group: included anemic mothers who were otherwise healthy, i.e., free from significant medical, surgical and obstetrical. Thirty placentas, i.e., 50% of total cases, were studied in this series. Only 5 cases had the minor obstetric history, i.e. previous MTP. There were eleven primi, twelve second gravida and seven third gravida. All the cases were diagnosed clinically and hematologically as anemia. Blood hemoglobin level ranged from 5.50 gm% to 10 gm%.

In anemic mothers, mean birth weight of the baby was found to be significantly less than that of control group (Table 2). This had been observed in case of both male and female babies, though, in general male babies weighed more than female babies.

Table 1: Baby birth weight and placental morphometric study in control (non- anemic) group of mother at term

Sex of baby	No. of cases	Avg. baby birth wt (kg)	Avg. pla. wt. (gm)	Avg. pla. vol. (ml)	Avg. pla. dia. (cm)	Avg. pla. thick (cm)	Avg. pla. Area (cm ²)	Avg. No. of cotyledon
Placenta with Male baby	17	2.60±0.28	473.5±17.5	400.88±14.38	18.38±1.0	1.78±0.2	265.86±22.7	17.47± 1.0
Placenta with Female baby	13	2.57±0.33	457.6±21.6	396.15±13.86	18.4±1.0	1.79± 0.1	266.24±23.0	17.46±1.1
All cases	30	2.58±0.29	466.6±20.6	398.8±14.1	18.56±1.7	1.79±0.1	266.03±22.4	17.46±0.1

Table 2: Baby birth weight and placental morphometric study in anemic group of mothers at term (test group)

Sex	No. of case	Avg. baby Birth wt. (kg)	Avg. pla. wt. (g)	Avg. pla. vol. (ml)	Avg. pla. Dia. (cm)	Avg. pla. Thick (cm)	Avg. pla. area (cm ²)	Avg. No of cotyledon
Placenta with Male baby	18	2.25±0.3	500±53.4	438.3±49.8	19.40±1.1	1.90±0.2	295.78±30.4	12.94±2.1
Placenta with Female baby	12	2.06±0.3	505.41±53.8	457.5±88.4	19.35±1.0	1.90±0.2	293.10±23.5	12.83±1.6
All cases	30	2.18±0.3	502.16±50.7	446.0±67.1	19.38±1.1	1.90±0.2	294.71±27.5	12.90±1.9

The mean baby birth weight at term in the control group was 2.589 kg, but in the test group it is decreased to 2.182 kg. This decrease of 407 gm was highly significant (p value <0.001). The mean placental weight at term in control group was found to be 466.7 gm, but in test group it increased (502.2 gm), this was statistically significantly (p value <0.025).

The mean placental volume at term in control group was 398.8 ml, but in test group it increased to 446.0 ml. This increase was statistically highly significant. (p-value= 0.000689).

The mean placental area at term in control group is 266.0 cm², in test group it was 294.7 cm², it was statistically significant. (p-value i.e. 4.56328E-05). Numbers of cotyledons were found to be significantly reduced in anemic mothers. Comparative statements of gross morphological features of placenta yielded some interesting results (Table 3).

Change of shape of placenta could not be related to anemia. A marginal increase in the number of ill-defined cotyledons and succenturiate lobe could be observed in anemic mothers. The incidence of eccentric insertion of cord was slightly lower, that of central insertion was same; while that of marginal insertion was slightly greater in anemic mothers. Peculiarly enough, marginal membrane attachment was found to more while circumvallate attachment was less in the anemic than in non-anemic mothers. Occurrence of morphological features, like subchorionic fibrosis or cyst; retroplacental clot, gross calcification, or placental infarction etc were found to be significantly higher in anemic mothers in comparison to non-anemic control group.

Table 3: Comparisons of gross morphological changes of the placenta in non-anemic mothers and anemic mothers at term

S. No	Morphological features	Non-anemic mothers	Anaemic mothers
1	Shape		
	Circular	67%	67%
	Oval	33%	33%
2	Cotyledons		
	Ill-defined cotyledons	17 %	20%
	Succentuate lobe	–	03%
3	Insertion of cord		
	Eccentric	67%	60%
	Central	33%	33%
	Marginal	–	07%
4	Membrane attachment		
	Marginal	93%	90%
	Circum-vallate	07%	10%
5	Presence of sub-chorionic fibrosis	13%	17%
6	Presence of sub-chorionic cyst	7%	10%
7	Retro placental blood clot	10%	17%
8	Gross calcification	13%	20%
	Infarction	07%	17%

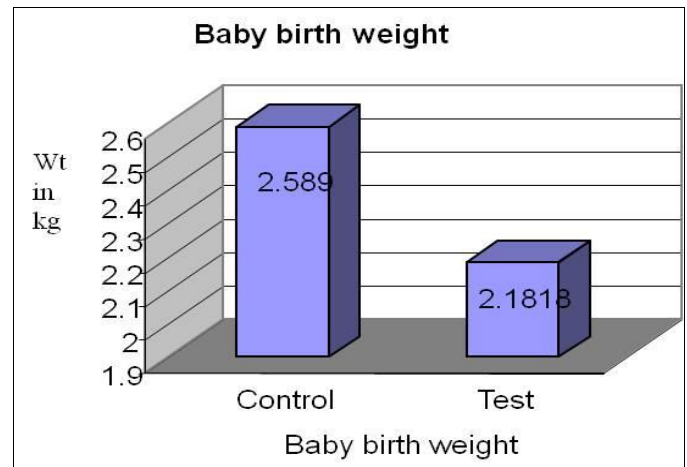


Fig. 3: Baby Birth weight

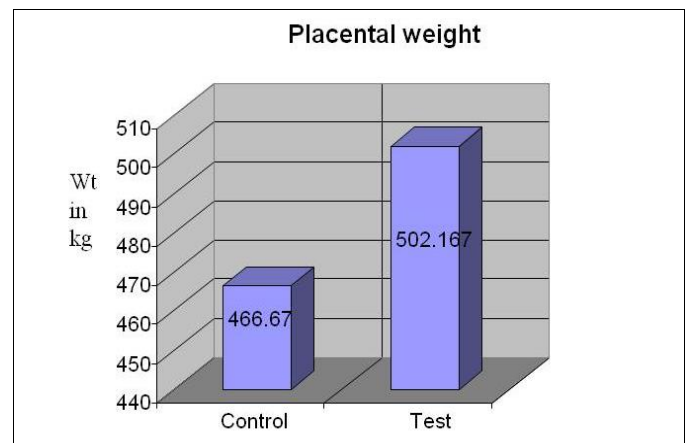


Fig. 4: Weight of the Placenta

DISCUSSION

The placenta is functionally the most important and vital organ related to intra uterine life. It is subjected to various defects and diseases just like the other vital organs of the body. Various clinical conditions such as anemia, diabetes, hypertension, etc have a detrimental effect on the placenta, which may seriously affect health and even life of the fetus.

Even though researches on this subject were/ are being carried out by various workers, studies on placental changes in anemia have lagged behind than that of diabetes, hypertension, etc. Present study was conducted to examine the macroscopic changes in placentas from normal (non-anemic) and anemic mothers.

A significant reduction of the baby birth weight had been observed in anemic mothers, as was expected (Fig. 3). The cause can be attributed to reduction in the ‘exchange-surface’ of placenta [34], directly related to the maternal hemoglobin level and hence anemia. To be precise, the low levels of placental iron or cord serum iron in severely anemic mothers suggests that fetal intake of iron is directly proportional to the level of available iron in the maternal blood [25].

The placental weight is the single most important factor reflecting fetal growth. From the study it has been seen that the mean weight of placenta at term was 466.67 (±20.69) gm in non-anemic group and 502.17 (±50.73) gm in anemic group (Fig. 4).

The findings in the non-anemic mothers of the present study are compared with results from other studies (Table 4). It can be noted that there is only slight difference in mean weight of term placenta published by various authors. It is also evident that placental weight maintains more or less a constant relation with the fetal weight. The placento-fetal weight ratio (P/F ratio) varies from 0.126 to 0.185, which is comparable to the findings (0.179) of the present study.

Though the mean birth weights of the babies were low, the mean placental weight and P/F ratio was observed to be similar to previous studies. Possibly low birth weights of the babies in the present series were due to low socio-economic status of the patients.

In the anemic group, mean placental weight was found to be significantly increased, possibly due to uniform physiological compensatory growth [35]. This increase in the placental weight was reported by the majority of the previous workers working with all sorts of anemia including iron-deficiency anaemia [10], and anemia due to low hematocrit [23]. The present study hence conformed to the findings and conclusion of the previous study.

Table 4: Comparison of placental weight, baby birth weight by different authors with the present study

Author	No. of cases	Gestational week.	Baby birth weight (g)	Placental weight (g)	P/F ratio
Little ^[36]	750	37-41	3215	451	0.14
Gruenwald <i>et al.</i> ^[37]	855	40	3001	425	0.15
Gruenwald ^[38]	800	37-38	3318	488	0.147
Younszai <i>et al.</i> ^[39]	85	37-42	3313	420	0.126
Shah <i>et al.</i> ^[40]	93	37-42	2814	522	0.185
Present study	30	38	2589	466	0.179

In the present study, it has been shown that the volume of the placenta has been increased to 446.00 (± 67.19) ml in anemic group than the control group which was 398.83 (± 14.12) ml. (Fig. 5).

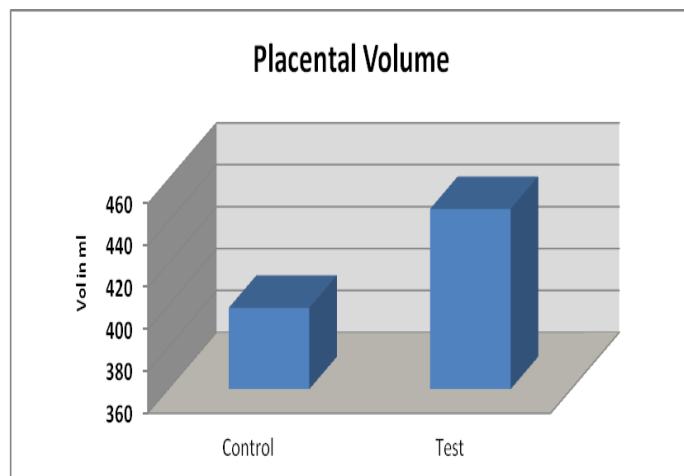


Fig. 5: Placental Volume

Kuizon *et al.* ^[11] were report that anemic mothers had placental hypertrophy. The hypertrophy was probably a compensatory physiological response to ensure adequate oxygen supply to the fetus.

The morphologic picture of placenta shows great variations. These diverse variations often proved difficult to differentiate a pathological placenta from a normal one. However, observation of the present study is discussed in light of different reports published as follows:

The usual description of the shape of the placenta is that it is a discoid flattened mass with an approximately circular margin ^[4]. Variation in shape includes rounded, oval, irregular, tripartite or rarely fenestrated placentas ^[3]. These variations can be associated with premature due to toxemia, severe anemia, Rh-incompatibility etc, but whatever might be the cause, clinical significance could not be attributed to any of these variations ^[5]. The shape bears no correlation with maternal and fetal status ^[5,12]

& it was in concurrence with our present study with anemic mothers. In the present study it is seen that shape of placenta is circular in 67% and oval in 33% of cases in both, anemic and non-anemic groups at term.

Cotyledons also vary in number. Nesbit ^[24] was observed as many as 20 cotyledons, while Woodling *et al.* ^[32] were observed as low as 8 cotyledons in normal placenta. In the present study, mean number of cotyledons with control group was 17.46 ± 1.04 , while that in test group was 13 ± 1.9 ; indicating that number of cotyledons was significantly decreased in anemic mothers. A significant reduction was reported by Singla *et al.* ^[25] and it was found to be directly due to severe anemia. Once again, findings of the present study regarding the number of cotyledons are at par with the previous studies.

The umbilical cord, although usually attached near the centre of the organ, may reach it at any point between its centre and margin. Previous studies had reported eccentric (73%), central (18%) and battledore (7--9%) insertion of the cord ^[41], but neither of the modes of insertion of cord was associated with excess incidence of abortion, premature labor or neonatal asphyxia ^[42]. In the present study no such significant anomalous membrane insertion has been noted. Though 10% of insertions of cord in total cases were circum vallate in anemia, but the incidence had no clinical effect except slight reduction in baby birth weight.

Fibrin plaques and nodules are normally distributed beneath the chorionic plate of the term placenta. The amount of this sub-chorionic fibrin and its distribution varies considerably. In the present study, it has been found that the incidence of sub-chorionic fibrosis is 13% and 17% for the anemic and non-anemic group respectively showing an increased incidence of sub-chorionic fibrosis in anemia. Nesbit ^[24] was found that sub-chorionic deposition of fibrin was present nearly in every placenta after 24 weeks of gestation. The presence of this feature was considered as a sign of maturity ^[32]. However, Fox ^[27] showed an incidence of sub-chorionic fibrosis in anemic mothers to be about

20%. Thus, the result of our present study is in accordance with the findings of the previous studies.

Placental calcification is often regarded as evidence of placental senescence or 'degeneration', and is of no pathological or clinical importance^[24]. Small calcareous deposition or plaques could be recognized even with the naked eyes in term placenta^[43]. A direct relationship has been observed with increasing gestational age. Maternal age is five times more influential than gestational age in this regard^[44].

The incidence of calcification in the present study showed significant increase in the test group than in the control. An increase in the incidence of sub-chorionic cyst was observed in the current study. The observation matches with the previous studies^[23,29].

Retroplacental haematomas have been attributed to rupture of uteroplacental artery or obstruction of the placental venous outflow. Small sized haematomas without fetal effects were observed in the present study and the incidence was 17% in test group, which was significantly higher than in the control group (10%).

Excessive infarction occurs only against a background of a markedly abnormally vasculatures and a restricted maternal blood flow to the placenta and it is these factors, rather than the loss of villi due to infarction, which are the real cause of the fetal complications. The incidence of placental infarction was reported to be around 20–30.5% in one study^[36] and 25% placentas from uncomplicated pregnancies showed less than 5% involvement of villous parenchyma, suggesting no clinical significance^[27,45]. However, extensive placental infarction involving more than 10% of villous parenchyma is associated with high incidence of fetal hypoxia, growth retardation and intrauterine fetal death^[45]. In the present study, the infarcts detected with control group (7%) as well as in the test group (17%) were examined and found to be small and involved less than 5% of villous parenchyma, thus maintaining a similarity of observations with the previous study in this field.

CONCLUSIONS

In the present study, it was observed that the placenta has considerable functional reserve capacity; it can repair any damage it suffers with commendable ease. We concluded that the placenta shows compensatory mechanisms which tend to limit the ill-effects of both tissue injury and unfavorable maternal milieu like anemia. Most of the findings of the present study were in accordance with the previous studies in this field.

REFERENCES

- [1] Benirschke K. The Placenta: How to Examine it and what you can learn- Contemp Obstet and Gynaecol., 1981; 17: 117-19.
- [2] Salafia CM, Silberman I, Herrera NE, Mahoney MJ. Placental pathology at term associated with elevated midtrimester maternal serum alpha-fetoprotein concentration. Am. J. Obstet. Gynecol., 1988; 58: 1064-66.
- [3] Dutta DC. Text book of Obstetrics. 5th ed., India; New Central Book Agency, 2001: pp. 29.

- [4] Patricia Collins. Grays Anatomy. 38th ed., New York; Churchill Livingstone-Medical division of Pearson professional Limited, 1995: pp.166.
- [5] Shah RK, Jagiwala KS, Vyas PK. Placental morphology and fetal growth in normal and abnormal pregnancies. J. Obstet. Gynaecol. India, 1985; 35: 1089-94.
- [6] Reshetnikova OS, et al. Placental histomorphometry and morphometric diffusing capacity of the villous membrane in pregnancies complicated by maternal iron-deficiency anaemia. Am J. Obstet. Gynecol., 1995; 173: 724-27.
- [7] Garrow JS, Hawes SF. The relationship of the size and composition of the human placenta to its functional capacity. J. Obstet. Gynaecol. Br. Commou., 1971; 78: 22-28.
- [8] Pryse-Davies J, Beazley JM, Leach G. A study of placental size and chorioamnionitis in a consecutive series of hospital deliveries. Br. J. Obstet. Gynaecol., 1973; 80: 246-51.
- [9] Agboola A. Placental changes in patients with a low haematocrit. Br. J. Obst. Gynecol., 1975; 82: 225-27.
- [10] Levario-Carrillo M, et al. Effect of iron-deficiency anaemia on placenta and birth weight. Gynecol. Obstet. Mex., 2003; 71:75-81.
- [11] Kuizon MD, Cheong RL, Ancheta LP, Desnacido JA, Macapinlac MP, et al. Effect of anaemia and other maternal characteristics on birth weight. Hum. Nutri. Clin. Nutri., 1985; 39(6): 419-26.
- [12] Shanklin DR. The Human Placenta: A clinic-pathological study. J. Obstet Gynaecol Br Commonw., 1958; 11: 139.
- [13] Aherne W, Dunnill MS. Quantitative aspects of placental structure. J. Pathol. Bacteriol., 1966; 91: 123-139.
- [14] Hendrick CH. Study on placenta. J. Obstet. Gynecol. Br. Commu., 1964; 24: 357-65.
- [15] Beischer NA, Sivasamboor, Vohra S, Silpisornkosal S, Reid S. Placental hypertrophy in severe pregnancy anaemia. J. Obst. Gynaecol. Br. Commu., 1970; 77: 398-409.
- [16] Clavero-Nunez JA. La placenta de las cardiacas. Revista Espanola de Obstetricia., 1963; 22: 129-34.
- [17] Godfrey KM, Redman CW, Barker DJ, Osmond C. The effect of maternal anaemia and iron deficiency the ratio of fetal weight to placental weight. Br. J. Obst. Gynecol., 1991; 98: 886-91.
- [18] Kruger H, Arias-Stella J. The Placenta and the newborn Infant at high altitudes. Am. J. Obst. Gynecol., 1970; 106: 586-91.
- [19] Fox H, Sen DK. Placenta extrachorialish A clinico-pathological study. J. Obstet. Gynaecol. Br. Commu., 1972; 79: 32-35.
- [20] Rolscheu J. Circumvallate Placenta and Intrauterine Growth Retardation. Acta. Obstetrica et Gynaecologica Scadinavica Suppl., 1978; 72: 11-14.
- [21] Sandstedt B. The placenta and low birth weight. Curr. Topics Pathol., 1979; 66: 1-55.
- [22] Lademacher DS, et al. Circumvallate Placenta and Congenital malformation Lancet, 1981; I: 732.
- [23] Benirschke K, Kaufmann P. Pathology of Human Placenta. New York 2nd ed: Springer Verlag., 1990; pp. 130.
- [24] Nesbitt REL, Novak ER, Woodreff JD, In Novak's Gynaecologic and Obstetric pathology; 7th edition, 1974.
- [25] Singla PN, Chand S, Khanna S, Agarwal KN. Effect of maternal anemia on the placenta and the newborn. Acta Paediatr. Scand., 1978; 67(5): 645-48.
- [26] Wentworth P. Circumvallate Circum marginate Placentas. Am. J. Obstetrics Gynaecol., 1968; 102: 44-47.

- [27] Fox H. The significance of placental infarction in perinatal morbidity and mortality. *Biologica. Neonatorum.*, 1967b; 11: 87-105.
- [28] Brown HL, Miller JM, Khawli D, Gabert HA. Premature placental calcification in maternal cigarette smokers. *Obst. Gynaecol.*, 1988; 71: 914-17.
- [29] Fox H. The significance of villous syncytial knots in the human placenta. *J. Obstet. Gynecol. Br. Commu.*, 1965; 72: 347-55.
- [30] De-Sa OJ. Rupture of fetal vessels on placental surface. In: *Archives of Diseases in Childhood*, 1971; 46: 495-501.
- [31] Robertson WB, Bosens I, Dixon H G. Utero-placental Vascular Pathol. *European J. Obs. Gynaecol. Reprod. Biol.*, 1975; 5: 47-65.
- [32] Woodling BA, Kroener JM, Puffer HW, Furukawa SB, Anderson G, et al. Gross Exam of the Placenta. *Clin. Obstet. Gynaecol.*, 1976; 19(1): 21-44.
- [33] Pearlstone M, Baxi L. Subchorionic haematoma. A review: *Obstetrical and Gynaecological Survey*, 1993; 48: 65-68.
- [34] Dhall U, Chopra N, Tiwari S, Dhall R. Morphometry of placenta in anaemia. *J. Anatomical Soc. India*, 1995; 44(2): 103-10.
- [35] Huang A, et al. Quantitative (Stereological) study of the placental structures in pregnancies complicated by iron-deficiency anaemia. *Eur. J. Obstet. Gynecol. Reprod. Biol.*, 2001; 97(1): 59-64.
- [36] Little WA. Placental infarction. *Am. J. Obst. Gynecol.*, 1960; 15: 109-30.
- [37] Gruenwald P, Mihn HN. Evaluation of body and Organ weights in perinatal pathology. *Am. J. Obst. Gynaecol.*, 1961; 82: 312-19.
- [38] Gruenwald P. Growth of human fetus. *Adv. Reprod. Physiol.*, 1967; 2: 279-309.
- [39] Younszai MK, Peloso J, Haworth JC. Fetal growth retardation in rats exposed to cigarette smoke during pregnancy. *Am. J. Obst. Gynecol.*, 1969; 104(8): 1207-13.
- [40] Shah RK, Jaguvala KS, Vyas PK. Placental morphology and fetal growth in normal and abnormal pregnancies. *J. Obst. Gynaecol. India*, 1984; 35: 1089-92.
- [41] Mukherjee B, Lal Ram. Relation between fetal weight and placental size. *J. Anat. Society Ind.*, 1983; 32 (3):124-26.
- [42] Fox H. *Pathology of the Placenta*. Saunders, Philadelphia; WB Saunders, 1978.
- [43] Masters M, Clayton SG. Calcification of the human placenta. *J. Obstet. Gynecol. Br. Emp.*, 1940; 47: 437-43.
- [44] Tindall VR, Scott JS. Placental calcification: A study of 3025 singleton and multiple Pregnancies. *J. Obst. Gynecol. Br. Commu.*, 1965; 72: 356-73.
- [45] Naeye RL. Placental infarction leading to fetal; or neonatal death. A prospective study. *J. Obst. Gynecol.*, 1977; 50(5): 583-88.

International Journal of Life Sciences Scientific Research (IJLSSR)**Open Access Policy**

Authors/Contributors are responsible for originality, contents, correct references, and ethical issues.

IJLSSR publishes all articles under Creative Commons Attribution- Non-Commercial 4.0 International License (CC BY-NC).

<https://creativecommons.org/licenses/by-nc/4.0/legalcode>

**How to cite this article:**

Mondal GC, Baske A, Biswas S. Morphological Changes of Placenta Associated with Maternal Anaemia *Int. J. Life Sci. Scienti. Res.*, 2017; 3(5):1400-1407. DOI:10.21276/ijlssr.2017.3.5.23

Source of Financial Support: Nil, **Conflict of interest:** Nil