

Evaluation of Results of Intramedullary Fixation of Paediatric Fracture Shaft Femur by Titanium Elastic Nail

Deepak Srivastav^{1*}, Mithlesh Kumar², Arpita Mohan³

¹Assistant Professor, Department of Orthopaedics, Hind Institute of Medical Sciences, Lucknow, India

²Assistant Professor, Department of Orthopaedics, Government Medical College, Azamgarh, India

³Assistant Professor, Department of Dentistry, Hind Institute of Medical Sciences, Lucknow, India

*Address for Correspondence: Dr. Deepak Srivastav, Assistant Professor, Department of Orthopaedics, Hind Institute of Medical Sciences, Lucknow, India

Received: 03 June 2017/Revised: 12 July 2017/Accepted: 26 August 2017

ABSTRACT- Background: Femoral shaft fractures are the most common fractures in paediatric orthopaedic age group. There are distinct methodologies to treat them. Elastic stable intramedullary nailing is one in every of them and a longtime and reliable methodology for treating these fractures.

Methods: Total 65 femoral shaft fractures in 60 children aged 6–14 years were fixed with titanium intramedullary elastic nails under image intensifier control between July 2013 and June 2017. Two nails of proper and equal diameter were used for fracture fixation. No external splint was used after surgery. Outcomes assessed on the basis of Flynn et al scoring criterion.

Results: All patients achieved complete healing at a mean of 9.5 weeks. 51 fractures reduced by closed means but 14 needs open reduction. Common size of elastic nail used was 3 mm. No major complication was recorded all were minor and can be taken care off. Most common entry site (skin irritation) was recorded in 10 patients. 90% had excellent result and 10% had satisfactory.

Conclusion: Elastic stable intramedullary nailing is the method of choice for the Femoral shaft fracture in paediatric patients, because it was minimally invasive and provide six point fixation and shows very good functional and cosmetic result. It allows early ambulation and shorter hospital stay and higher parent satisfaction. ESIN also provide flexural, translational and rotational stability as well.

Key-words- Elastic stable intramedullary nailing (ESIN), Titanium elastic nail (TEN), Femoral shaft fracture, Paediatric

INTRODUCTION

Surgical treatment of long bone fractures in children must first consider the fact that excellent results can be achieved with non operative treatment, with reported union rates of more than 90% and 100% full functional recovery. [1] Occasionally reduction cannot be maintained due to excessive shortening, angulations, or malrotation at the fracture site, making operative intervention necessary. [2] Fracture treatment in children relies on rapid healing and spontaneous correction of angulated fractures; therefore most of the diaphyseal fractures can be treated with plaster alone. Operative treatment of children's fracture is often looked at critically. [3]

Conservative treatment of long bone shaft fractures in children is by traction followed by plaster, hip spica or a Thomas splint. Conventional treatment gives good results in children under 6 years of age. But above that age, all long bone fractures in children cannot be treated by conservative methods. There is possibility of loss of reduction, shortening, angulations and malunion. Plaster immobilization has its own complications like pressure sores, nerve palsies, soiling of the skin and the plaster, breakage of plaster, joint stiffness. The child is immobilized and needs an attendant for personal care. Various methods are used to treat paediatric long bone fractures and these include traction, [4] splints/orthotics, plaster casts, [5] external fixation, [6] open reduction and internal fixation using plates and screws [7] or intramedullary stabilization with a rod. [8] These modalities are not without complications. [9-11] In addition, some require prolonged hospital stay, periods of inactivity and aesthetically unsatisfactory scars. Reeves *et al.* [12] was reported that the cost of non operative treatment is 40% higher than operative treatment. Over recent years the use of elastic stable intramedullary nails has dramatically increased with the

Access this article online

Quick Response Code	Website: www.ijlssr.com
	 DOI: 10.21276/ijlssr.2017.3.5.16

introduction of a variety of nails for paediatric fractures.^[13]

Over the past two decades the advantages of fixation and rapid mobilization has been increasingly recognized health care cost containment and a desire for early discharge from the hospital have become important factors in treatment of long bone shaft fracture. As a result newer techniques have become popular. An ideal fixation device for paediatric long bone fracture would be a load sharing internal splint maintaining reduction for a few weeks until callus forms. Most importantly implant should endanger neither the physis nor the blood supply. Titanium implants are increasingly being used for elastic stable intramedullary nailing. The material properties of titanium confer advantages for an implant used to stabilise paediatric long bone fractures. Titanium elasticity limits the amount that the nail is permanently deformed during insertion. More importantly elasticity promotes callus formation by limiting stress shielding. Titanium also has excellent biocompatibility.

The biomechanical principal of the TENs is based on the symmetrical bracing action of two elastic nails inserted into the metaphysis, each of which bears against the inner bone at three points.^[14,15] This produces the following four properties that are essential for achieving optimal results; flexural, axial, translational and rotational stability.^[14] The ESIN has the benefits of early immediate stability to the involved bone segment, which permits early mobilization and return to the normal activities of the patients, with very low complication rate.^[16,17]

MATERIALS AND METHODS

It is a prospective study, which was conducted in the department of orthopaedic, Hind Institute of Medical Sciences, Lucknow, Uttar Pradesh, India between July 2013 and June 2017; between 60 paediatric patients (40 male and 20 female) with 65 femoral diaphyseal fractures were treated by internal fixation with intramedullary titanium elastic nails.

Inclusion Criteria

- ❖ Age Group between 6-14yrs of age
- ❖ Displaced fracture, with or without comminution
- ❖ Multiple fractures
- ❖ Closed and open up to Gustillos grade-II fractures

Exclusion criteria

- ❖ Children <6 and >14 yrs of age
- ❖ Metaphyseal fracture
- ❖ Undisplaced fracture
- ❖ Open Gustillo grade-III fractures
- ❖ Pathological fractures

The diameter of TENs nail was determine by formula as stated by Kaser and Beaty.^[18]

Nail diameter= (Medullary canal diameter/ 2)- 0.5

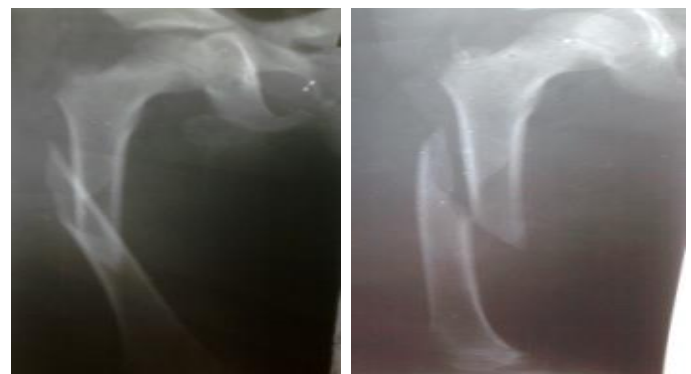Operative technique: Under general or spinal anaesthesia, the patient was placed supine on an

orthopaedic table with traction by assistant or by using traction table ensuring correct linear and rotational alignment clinically and radiologically using an image intensifier.

The essential prerequisite is accurate pre-bending of an elastic titanium nail so that the apex of the bend will lie at the fracture site. Its length should be selected on the basis of pre-operative radiograph of known magnification, and confirmed on the limb before insertion.

In general, the entry site of nail will be in the metaphysis of the bone. It is tempting to make a small stab incision to make insertion. Under image intensifier, the cortex can be breached with an awl or drill according to individual, TENs nail of proper diameter and length tapped along the medulla with the tip angled away from the cortex. The temptation to rotate the nail back and forth should be resisted. If possible, the fracture should be reduced by manipulation and the nail advanced across the fracture site.

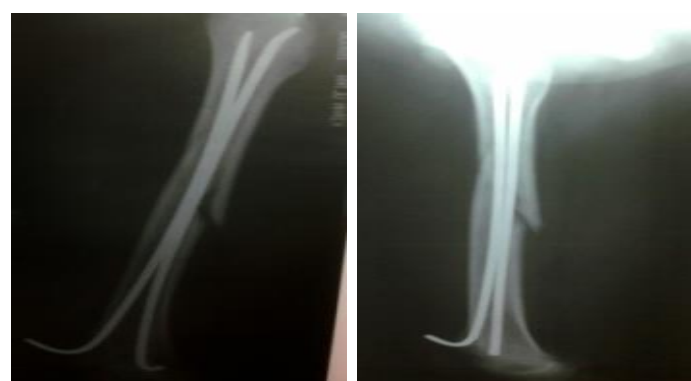Insertion of the later nail in a similar fashion but from the opposite side of the bone. All nails should be inserted up to the fracture site, the fracture reduced, and the nails tapped across the fracture site in an alternating manner for perhaps 1 to 2 cm into the far segment. All nails can then be knocked home, leaving sufficient nail exposed at the site of insertion to enable subsequent removal.



A (AP view)

B (Lateral view)

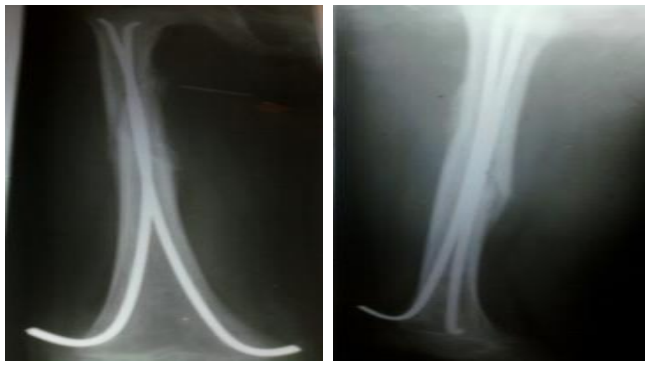
Fig. 1: Pre-Operative X-ray of Right Femur of 11 yr Boy



A (AP view)

B (Lateral view)

Fig. 2: Post-Operative X-ray of Right Femur of 11 yr Boy
AP = Antero Posterior



A (AP view)

B (Lateral view)

Fig. 3: Post-Operative X-ray of Right Femur of 11 yr Boy after 9 Weeks

AP = Antero Posterior

Post operative rehabilitation: No external splints were used. The children were started on non weight bearing crutch walking and knee physiotherapy 2–3 days after the surgery and were ready for discharge 3–4 days after surgery. The children with polytrauma stayed on for a longer period in the hospital because of associated injuries. The children were encouraged to attend school 3–4 weeks after surgery, avoiding sports and physical training. The school authorities consented to this and allowed an attendant for the children.

Full weight bearing was allowed after clinic-radiological fracture union. The union was defined clinically by the absence of bony tenderness and abnormal mobility at the fracture site and no pain at the fracture site on weight bearing. The radiological fracture union was defined by the presence of callus bridging the fracture and partial obliteration of the fracture lines in 2 views perpendicular to each other. The children were assessed for any malunion both linear and rotational, and for any limb length disparity. The wires were removed without anaesthesia in the outdoor with the help of pliers and t-handle.

RESULTS

Among the 60 children of 6–14 yrs of age, maximum 30 children (50%) were in the age group 9–11 year. Out of 65 diaphyseal fracture femurs 43 were on the right side. Mostly children were hurted by road traffic accident 35 and 25 by sports related injuries. On the basis of pattern 26 were transverse, 20 oblique, 15 spiral and 4 were communitated. Most of them 49 children were not associated with any other injuries but 6 had clavicle fracture, 2 had pelvic injury and 3 were associated with head injury. 34 fractures were closed and 20 of grade I, 11 were grade II open fracture.

All patients underwent surgery under general anaesthesia and titanium nails were used in each patient. Most of the children (35) were operated within a week of injury. Cases operated late included that were associated with head injury or wound. The average operative time was 45 min (range 20–75 minutes). 51 (78.4%) patients the fracture was reduced by closed means; whilst in the other 14 (21.6%) open reduction was required. Open reduction needed a minimum exposure with minimum blood loss,

minimum handling of periosteum and, no increase in the morbidity or alteration in the post operative rehabilitation. The commonest titanium nail size used was 3 mm. 80% (48) patient were discharged within 3 days of operation on oral drugs which was one of the big advantages in comparison to conservative management but one child who develops infection post-operatively had stayed for 20 days till the infection controlled.

All patients achieved complete clinic-radiological healing at a mean of 9.5 weeks (range 6–15 weeks). Closed fractures healed more quickly (mean 8.3 weeks) than open fractures (mean 12.6 weeks). In a subjective measure of outcome at follow-up, 70% of the patients were very satisfied and 30% satisfied; no patients or parents reported their outcomes as not satisfied. Routine removal of the nails was undertaken in all patients. At follow up patients went on to osseous union and regained a full range of movement after rehabilitation. There were no cases of delayed union, non-union or malunion. After removal of the nails all patients regained full function and all complications resolved.

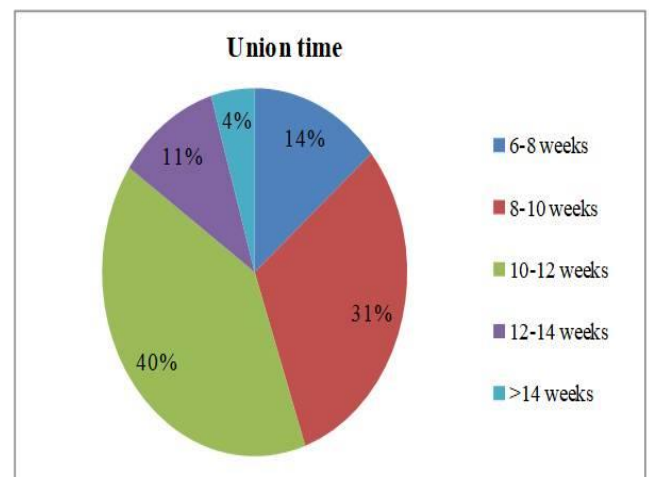


Fig. 4: Showing time taken for radiological union

Complications: Most common complication found was entry site skin irritation in 10 patients, which was subsided after nail removal. Exuberant callus formed in children with head injury, but this did not affect the final outcome. Others were protrusion of nail in one patient, infection develops in one patient, who was controlled with antibiotics and nail removed early and subsequently settles. Joint stiffness develops in two patients as they were not doing exercise, recovered with proper physiotherapy. There was no instance of loss of reduction, or nail migration during post-operative period. No clinically significant deformities and any limb length discrepancy were observed.

Table 1: Complications of Intramedullary fixation of fracture shaft femur by elastic nail

S. No	Complications	No. of cases (n=60)
1	Entry site irritation	10
2	Superficial infection	1
3	Deep infection	None
4	Limb length discrepancy	None
5	Refracture	None

Classifying our treatment outcomes based on the ten outcome scoring system by Flynn *et al.* [17], we found 90% excellent result, 10% satisfactory result and 0% poor result.

Table 2: Flynn *et al.* [17] scoring criteria for TENS

	Excellent	Satisfactory	Poor
Limb length inequality	< 1.0 cm	1.0-2.0cm	> 2.0 cm
Malalignment	<5°	5-10°	>10°
Pain	None	None	Present
Complications	None	Minor & resolved	Major & lasting morbidity
No. of patients (60)	54	6	0

DISCUSSION

The majority of emergency in most trauma centers are fractures of long bones. Although the majority of long bone shaft fractures in children can be treated with closed reduction and casting, occasionally surgical stabilization is required. Historically, external fixation has been the treatment of choice; however, risk includes pin track infections, non-union, and refracture [2,16]. Reamed locked intramedullary nails, while shown to be effective in the skeletally mature, pose unnecessary risk to the long bones physis, and have limited indications in those children with growth remaining. For femoral fractures may increase risk of avascular necrosis if fossa pyriformis is used as an entry point. [2] The elastic stable intramedullary nailing (ESIN) is now commonly used for the treatment of paediatric long bone fractures and their use has minimized the surgical scarring previously caused by open reduction and plating. [13] This method achieves biomechanical stability from the divergent “C” configuration which creates six points of fixation and allows the construct to act as an internal splint. [2,19] The ESIN provide stable and elastic fixation, allowing for controlled motion at the fracture site which results in healing by external callus. Several studies have demonstrated the safety and efficacy of this technique [1,17,20-23]. The ESIN is not without the possibility of complication. Complications usually are based on

mistakes concerning the indication or technical errors [24,25]. The most common reported complications associated with these techniques include infection, over growth, entry site skin irritation and re-fracture. [2,13,22] The most common complication was irritation of skin at the entry site. We have not observed any major complications. This is similar with complication rate reported by previous studies [2,13,24,25].

Age, fracture pattern, fracture location, soft tissue injury, presence of other fractures, physician and family preference, and the social situation all affect the treatment of a child with femoral shaft fractures. Treatment modalities include traction, immediate spica casting, traction followed by spica casting, external fixation, plating, flexible nailing, and intramedullary nailing. [17,26] Fixation by flexible nails is appropriate for patients over the age of six years. [17,26,27] Usually, femoral shaft fractures in children younger the age of six years is treated conservatively.

Khazzam *et al.* [28] evaluated use of TENs in the treatment of femoral fractures in 135 children. They recorded very good functional results, low complication rate and concluded that use of TENs in the treatment of femoral shaft fractures in children is successful regardless of patient age, fracture location, or fracture pattern.

The aim was to encourage the formation of bridging periosteal callus. The elastic nail, the bone and the muscles provide the stability. The muscle act as guy ropes, so even in an irritable child or the hyperactive child, the muscle activity just complements the fixation. Muscle action also causes spontaneous correction of any angular deformities. Micromotion allowed by the elasticity of the fixation promotes external bridging callus. The periosteum is not disturbed and being closed procedure, there was no evacuation of fracture hematoma or risk of infection. Callus formation is twice as fast as with conventional methods. [15]

CONCLUSIONS

Titanium elastic nailing seems to be more physiological and effective method of treatment of femoral shaft fractures in 6–14 years old children. It is simple, rapid and safe procedure with advantages of early union, early mobilization and early return to function with minimal complications. Elastic medullary nailing advantages make it a valuable choice to consider in managing children shaft femur fractures.

REFERENCES

- [1] El-Adl G, Mostafa MF, Khalil MA, et al. Titanium elastic nail fixation for paediatric femoral and tibial fractures. Acta. Orthop. Belg., 2009; 75: 512–20.
- [2] Sankar WN, Jones KJ, David HB, et al. Titanium elastic nails for pediatric tibial shaft fractures. J. Child. Orthop., 2007; 1: 281–86.
- [3] Huber R, Keller. Flexible intramedullary nailing as fracture treatment in children. J. Paed. Orthop., 1996; 16: 602-05.
- [4] Pearce MS. Calcaneal pin traction in the management of unstable tibial fractures. Aust. NZJ. Surg., 1993; 63: 279–83.

- [5] Pollak AN, Cooperman DR, Thompson GH. Spica cast treatment of femoral shaft fractures in children- The prognostic value of the mechanism of injury. *J. Trauma.*, 1994; 37: 223–29.
- [6] Blasier RD, Aronson J, Tursky EA. External fixation of pediatric femur fractures. *J. Pediatr. Orthop.*, 1997; 17: 342–46.
- [7] Caird MS, Mueller KA, Puryear A, Farley FA. Compression plating of pediatric femoral shaft fractures. *J. Pediatr. Orthop.*, 2003; 23: 448–52.
- [8] Buford D, Christensen K, Weatherall P. Intramedullary nailing of femoral fractures in adolescents. *Clin. Orthop. Relat Res.*, 1998; 350: 85–89.
- [9] Skaggs DL, Leet AI, Money MD, Shaw BA, Hale JM, et al. Secondary fractures associated with external fixation in pediatric femur fractures. *J. Pediatr. Orthop.*, 1999; 19: 582–86.
- [10] González-Herranz P, Burgos-Flores J, Rapariz JM, Lopez-Mondejar JA, Ocete JG, et al. Intramedullary nailing of the femur in children. Effects on its proximal end. *J. Bone Joint Surg. Br.*, 1995; 77: 262–66.
- [11] Fernandez FF, Egenolf M, Carsten C, Holz F, Schneider S, et al. Unstable diaphyseal fractures of both bones of the forearm in children plate fixation versus intramedullary nailing. *Injury*, 2005; 36: 1210–16.
- [12] Reeves RB. Internal fixation versus traction and casting of adolescent femoral shaft fracture. *J. Pediatr. Orthop.*, 1990; 19: 551.
- [13] Helenius I, Lamberg TS, Kaariainen S, et al. Operative treatment of fractures in children is increasing. A population-based study from Finland. *J. Bone Joint Surg. Am.*, 2009; 91: 2612–16.
- [14] Kissel EU, Miller ME. Closed Ender nailing of femur fractures in older children. *J. Trauma*, 1989; 29: 1585–88.
- [15] Ligier JN, Metaizeau JP. Elastic Stable Intramedullary Nailing of femoral shaft fractures in children *J. Bone Joint Surg. Br.*, 1988, 70: 74–77.
- [16] Bar-On E, Sagiv S, Porat S: External fixation or flexible intramedullary nailing for femoral shaft fractures in children. *J. Bone. Jt. Surg. Br.*, 1997; 79: 975–78.
- [17] Flynn JM, Hresko T, Reynolds RA, et al. Titanium elastic nails for pediatric femur fractures- a multicenter study of early results with analysis of complicat. *J. Pediatr. Orthop.*, 2001; 21: 4–8.
- [18] Kaser JR, Beaty JH. Femoral shaft fractures. In: Rockwood and Wilkins Fractures in Children. 5th ed. NewYork Lippincott Williams Wilkins, 2001; 941–80.
- [19] Salem K, Lindemann I, Keppler P. Flexible intramedullary nailing in pediatric lower limb fractures. *J. Pediatr. Orthop.*, 2006; 26: 505–09.
- [20] Li Y, Stabile KJ, Shilt JS. Biomechanical analysis of titanium elastic nail fixation in a pediatric femur fracture model. *J. Pediatr. Orthop.*, 2008; 28: 874–78.
- [21] Mahar A, Sink E, Faro F, al: Differences in biomechanical stability of femur fracture fixation when using titanium nails of increasing diameter. *J. Child. Orthop.*, 2007; 1: 211–15.
- [22] Wall EJ, Jain V, Vora V, et al. Complications of titanium and stainless steel elastic nail fixation of pediatric femoral fractures. *J. Bone. Jt. Surg. Am.*, 2008; 90: 1305–13.
- [23] Metaizeau J, Stable elastic intramedullary nailing of fractures of the femur in children. *J. Bone. Jt. Surg. Br.*, 2004; 86: 954–57.
- [24] Rajan RA, Hawkins KJ, Metcalfe J, et al. Elastic stable intramedullary nailing for displaced proximal humeral fractures in older children. *J. Child. Orthop.*, 2008; 2: 15–19.
- [25] Fernandez FF, Eberhardt O, Wirth T. Elastic stable intramedullary nailing as alternative therapy for the management of paediatric humeral shaft fractures. *Z. Orthop. Unfall.*, 2010; 148: 49–53.
- [26] Leventhal JM, Thomas SA, Rosenfield NS, et al. Fractures in young children. Distinguishing child abuse from unintentional injuries. *Am. J. Dis. Child.*, 1993; 147: 87–92.
- [27] Simanovsky N, Porat S, Simanovsky N, et al. Close reduction and intramedullary flexible titanium nails fixation of femoral shaft fractures in children under 5 years of age. *J. Pediatr. Orthop. B*, 2006; 1529: 293–297.
- [28] Khazzam M, Tassone C, Liu XC, et al. Use of flexible intramed- ullary nail fixation in treating femur fractures in children. *Am. J. Orthop.*, 2009; 38: E 49–55.

International Journal of Life Sciences Scientific Research (IJLSSR) Open Access Policy

Authors/Contributors are responsible for originality, contents, correct references, and ethical issues.

IJLSSR publishes all articles under Creative Commons Attribution- Non-Commercial 4.0 International License (CC BY-NC).

<https://creativecommons.org/licenses/by-nc/4.0/legalcode>



How to cite this article:

Srivastav D, Kumar M, Mohan A: Evaluation of Results of Intramedullary Fixation of Paediatric Fracture Shaft Femur by Titanium Elastic Nail. *Int. J. Life Sci. Scienti. Res.*, 2017; 3(5):1360-1364. DOI:10.21276/ijlssr.2017.3.5.16

Source of Financial Support: Nil, **Conflict of interest:** Nil