

Comparative Study of Foramen Magnum in Dry Cadaveric Skull and 3D CT Images

Arjun Kumar¹, Pratishtha Potdar^{2*}, Kuldeep Singh³, Jagmohan Singh Dhakar⁴

¹Resident, Department of Anatomy, Rama Medical College & Research Institute Kanpur, India

²Associate Professor, Department of Anatomy, Santosh Medical College, Ghaziabad, India

³Professor & Head, Department of Anatomy, Badaayun Medical College, U.P., India

⁴Statistician cum Assistant Professor, Department of Community Medicine, Santosh Medical College, Ghaziabad, India

***Address for Correspondence:** Dr. Pratishtha Potdar, Associate Professor, Department of Anatomy, Santosh Medical College, Ghaziabad, India

E-mail: drpratishthagupta@gmail.com

Received: 01 Apr 2019/ Revised: 07 Jul 2019/ Accepted: 29 Aug 2019

ABSTRACT

Background: The anatomical knowledge of foramen magnum is helpful for forensic investigations, anthropological identification of unknown individual and intracranial surgeries. The aim of our study was to provide morphometric data of foramen magnum in dry human skulls and CT images, which can be applied for many invasive surgical as well as diagnostic procedures carried out in the brain.

Methods: In this study, 50 adult human skulls and 50 CT images were taken. The various parameter of the foramen magnum was calculated using a vernier caliper to an accuracy of 0.01 mm and the same parameters were also evaluated in adult CT brain images. The distributions of shapes were also assessed visually in foramen magnum of dry skull and CT images.

Results: In our study on 50 dry skulls, the mean antero-posterior diameter, transverse diameter were 34.08 ± 2.25 mm and 28.17 ± 2.85 mm as well as the same diameters in 100 CT images was 34.95 ± 2.42 mm in males and 32.64 ± 1.89 mm in females. The mean area of the foramen magnum in dry skull was 757.41 ± 115.09 mm² and in CT images was 788.95 ± 95.71 mm in males and 681.22 ± 66.97 mm in females. This data was then compared and analyzed with the various other studies.

Conclusion: The dimensions in CT images were significantly higher than the dry skull. The commonest shape found was oval followed by irregular; least was round in both dry skull and CT images. Hence, further study is required as foramen magnum has great clinical significance.

Key-words: Antero posterior, Foramen magnum, Morphometric dimensions, Transverse, Skull

INTRODUCTION

The knowledge of foramen magnum is of great importance for neurologist as well as radiologist as it is very important land mark due to its close relationship with brainstem and spinal cord. The margins of the foramen magnum are interiorly encroached by the occipital condyles, which articulate with the superior articular facets of the atlas ^[1]. The foramen magnum is protected by Soft tissue mass inferiorly ^[2,3]. This makes it

difficult to assess lesions in case of fractures etc but with CT imaging techniques a comparison between the dried skulls and CT images can help in more precise localization of lesion. The morphometric data of foramen magnum can be used for diagnosis of various congenital diseases such as Arnold Chiari malformation in which expansion of transverse diameter more than antero-posterior diameter ^[4]. The diameter of the foramen magnum is also needed before the surgery of the posterior cranial fossa lesions as greater contra lateral exposure required, where antero-posterior diameter is more. The morphological parameters of the foramen magnum are more in males than in females which can be utilized for differentiation of sex in various medico legal conditions ^[5]. Various studies of foramen magnum shown that the antero-posterior and transverse diameter is 3.5

How to cite this article

Kumar A, Potdar P, Singh K, Dhakar JS. Comparative Study of Foramen Magnum in Dry Cadaveric Skull and 3D CT Images. SSR Inst. Int. J. Life Sci., 2019; 5(5): 2372-2378.



Access this article online

<https://ijls.com/>

cm and 3 cm. Compression of brainstem due to various pathological conditions causes life threatening respiratory complications [6,7]. The craniometric points can be located and accurate measurements are achieved from CT scan images than on conventional radiographs [8]. CT scan has minimal superimposition of structures and allows better visualization of minute differences of density. The existing literature reveals numerous studies on dry skull using foramen magnum but very few have reported using CT scan. Sexual dimorphisms of the FM in three-dimensional (3D) CT have 81% accuracy in determining the Gender [9].

Further, foramen magnum parameter index is also utilized for differentiations of races among skull as there exist some racial relationships among different shapes of foramen magnum [10]. Thus considering the above importance of foramen magnum, we calculate the antero-posterior diameter, transverse diameter along with the measurement of area of foramen magnum in both dry human skull and CT images. We also analyzed variations of its shape which can be utilized by Clinicians for various surgical and diagnostic procedures.

MATERIALS AND METHODS

The present study of the foramen magnum was done on 50 dry skulls and 50 CT images in the Department of Anatomy, Rama Medical College, Hapur, India from February 2017 to August 2017.

Three dimensional CT head images were taken from. O. P. Gupta Imaging Centre, Meerut, India. Complete dry skulls of age group between (18–70 yrs) were taken from department after taking ethical clearance from ethical committee. The skulls that are broken or incomplete and those of children and old age were excluded from the study. All dimensions of foramen magnum in dry human skulls were measured with the vernier calipers with an accuracy of 0.01 mm. All dimensions were measured by two observers to prevent inter-observer error. The dimensions measured were included the following:

Antero-posterior diameter /Foramen magnum length (FML)- Antero posterior diameter was measured by taking a point on the middle of anterior margin to the point on the middle of posterior margin of the foramen magnum as shown in Fig. 1.

Transverse diameter/ Foramen magnum width (FMW)- The width of foramen magnum was taken by measuring

most prominent parts of the lateral curvature as straight transverse diameter (Fig. 2).

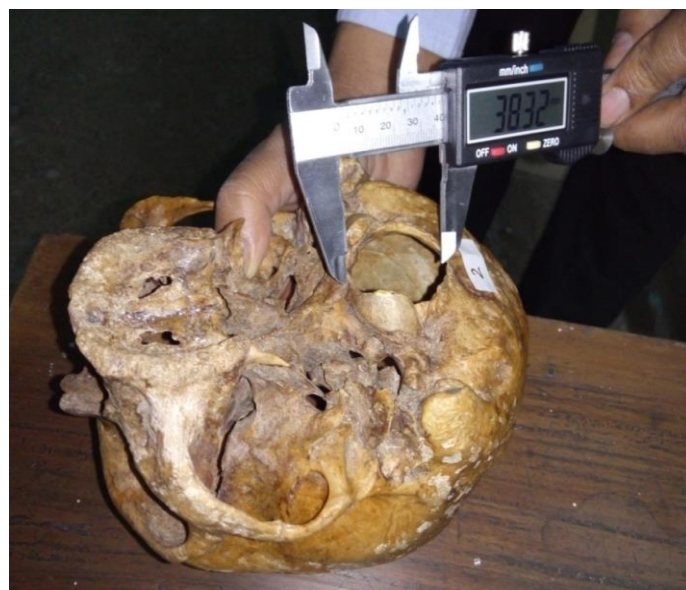

Fig. 1: Measurement of Antero posterior diameter

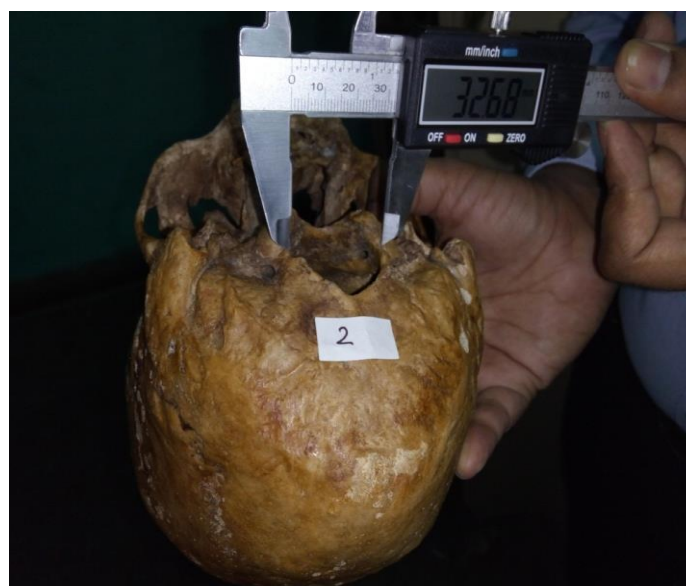

Fig. 2: Measurement of Transverse diameter

The two prongs of vernier calipers were fixed with screw over bony margins of foramen magnum then the length and width were recorded over the graduated metallic scale.

Foramen magnum Area (FMA)- The area of the foramen magnum was calculated as described by Kumar *et al.* [11] using Radinsky's formula:

$$\text{Radinsky's formula (FMA)} = 1/4 \times \pi \times \text{FML} \times \text{FMW}$$

whereas, $\pi = 22/7$, FML= Foramen magnum length, FMW= Foramen magnum width



Fig. 3: Diamond shape of FM

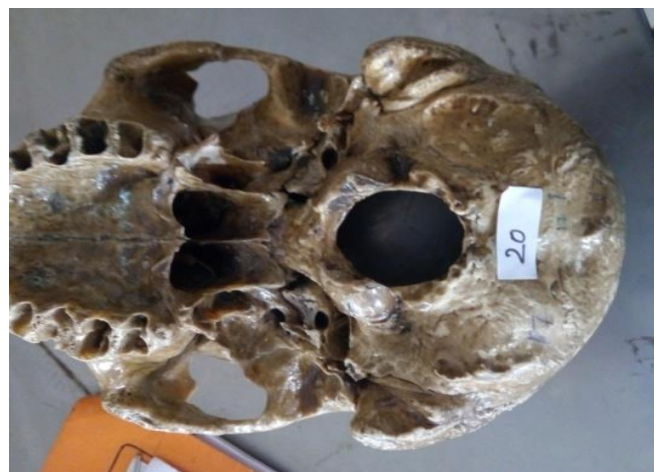

Fig. 4: Pentagonal shape of FM

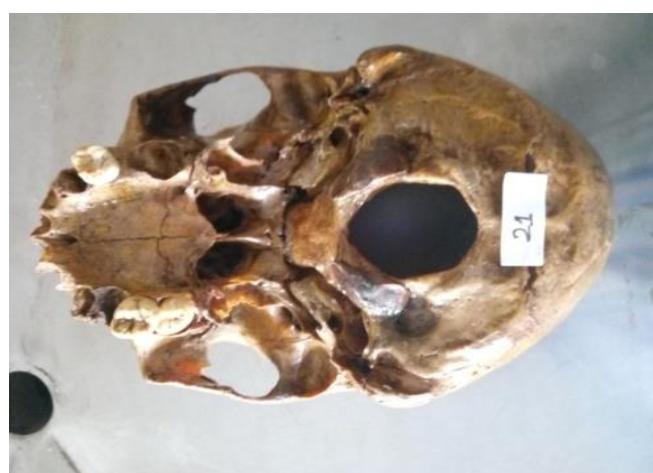

Fig. 5: Hexagonal shape of FM

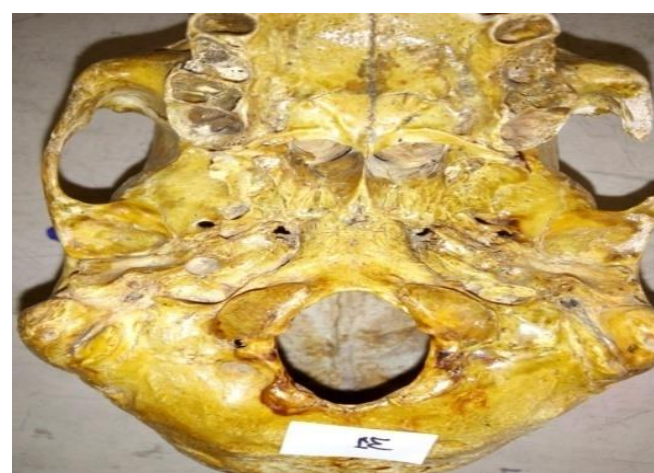

Fig. 6: Oval shape of FM

Variations in Shapes of foramen magnum– The frequency of distribution of various types of shapes were recorded. (Fig. 3 to Fig. 6).

The same parameters were also be evaluated in 100 CT Head images by the help of CT Machine Optima 660 GE 3D reconstruction was done with each slice thickness of 0.625 mm.

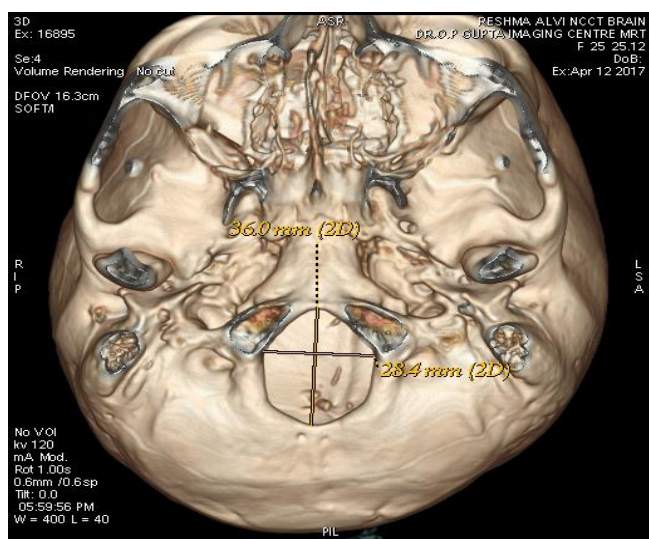


Fig. 7: 3D CT image of Antero- post diameter of FM in Male and Female

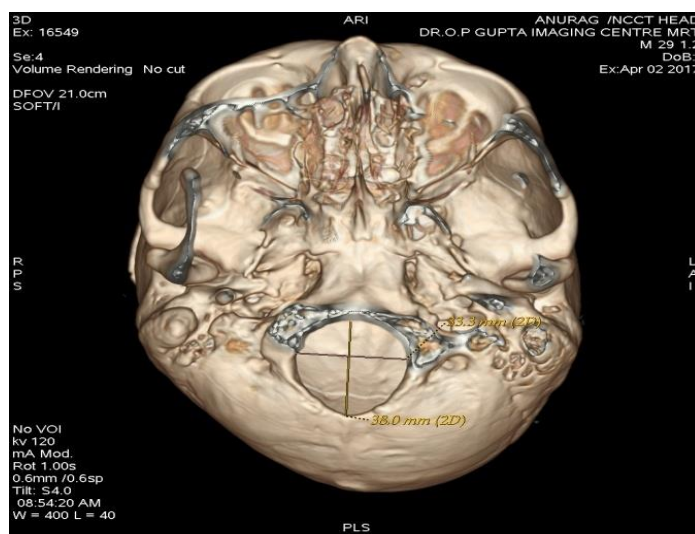


Fig. 8: 3D CT image of Transverse diameter of FM in Male and Female

Statistical Analysis- The data were collected, tabulated and statistically analyzed using the SPSS program and the appropriate test was applied.

RESULTS

The various parameters of foramen magnum recorded in 50 dry skulls and 50 CT images were represented in below given Table 1.

Table 1 shows the parameters of the foramen magnum was slightly higher in CT images as compared to dry cadaveric skull p-value was <0.001, which were statistically significant.

In our study, Table 2 shows the frequency of distribution of types of shapes in foramen magnum was oval 58%, hexagonal 10%, pentagonal 4%, around 12%, diamond 16%.

Table 3 shows that the data obtained from the present study were compared with reports from different authors. According to Mushed *et al.* [12], Chethan *et al.* [13], Radhakrishan *et al.* [14] shape were mainly rounded type while in this study and study was done by Radhika *et al.* [15] shape was mainly oval type.

Table 1: Morphometric data of foramen magnum in CT images of males and females and Dry cadaveric skull

Parameters	Dry skull (mm)	CT Images		P value
		Male (mm)	Female (mm)	
AP	34.08±2.25	34.95±2.42	32.64 ±1.80	<0.001
TR	28.17±2.85	28.64±2.21	26.73±2.50	<0.001
AREA	757.41±115.09	788.95±95.71	681.22±66.97	<0.001

P-value (<0.001)= Significant , AP= Antero posterior, TR= Transverse diameter

Table 2: Percentage of occurrence of various shapes of foramen magnum in dry bones and CT images

S.No.	Shapes	Dry skull (%)	CT images	
			Male	Female
1	Oval	29(58)	23	25
2	Irregular	0(0)	01	02
3	Hexagonal	05(10)	05	04
4	Tetragonal	0(0)	00	00
5	Pentagonal	02(4)	07	05
6	Round	06(12)	12	07
7	Diamond	08(16)	02	07

Table 3: Comparison of distribution of morphological types of shapes in foramen magnum with previous studies

Types of foramen Magnum	Murshed <i>et al.</i> [12]	Chethan <i>et al.</i> [13]	Radhakrishna <i>et al.</i> [14]	Radhika <i>et al.</i> [15]	Present Study
Oval	9(8.1%)	8(15.1%)	39(39%)	60(40%)	29(58%)
Round	24(21.8%)	12(22.6%)	28(28%)	30(20%)	6(12%)
Tetragonal	14(12.7%)	10(18.9%)	19(19%)	9(6%)	-
Hexagonal	19(17.2%)	3(5.6%)	-	9(6%)	5(10%)

Irregular	22(19.9%)	8(15.1%)	-	24(16%)	-
Pentagonal	-	-	-	-	2(4%)
Diamond	-	-	-	-	8(16%)

Table 4 shows that the data obtained from the present study was compared with reports from different authors. The measurement of antero-posterior dimension and transverse dimensions were the same as done by Borelli *et al.* [16], Kanchan *et al.* [17]; Santosh *et al.* [18].

In our study of foramen magnum area measurement is similar to the study done by Shepur *et al.* [19]; Singh and Talwar [20] and Acer *et al.* [21].

Table 4: Comparison of morphological parameters of foramen magnum in various studies

Previous studies (Year)	Antero-posterior diameter (mm)	Transverse Diameter (mm)
Murshed <i>et al.</i> [12]	35.9	30.45
Borelli <i>et al.</i> [16]	34.08	28.01
Gapert <i>et al.</i> [2]	35.91	30.51
Suazo <i>et al.</i> [6]	36.05	30.05
Chethan <i>et al.</i> [13]	31	25.2
Radhakrishna <i>et al.</i> [14]	34.04	28.63
Kanchan <i>et al.</i> [17]	34.51	28.98
Santhosh <i>et al.</i> [18]	34.37	28.98
Radhika <i>et al.</i> [15]	35.3	29.4
Kumar <i>et al.</i> [11]	36.78	30.05
Present study (2018)	34.08	28.17

Table 5: Interpretation and analysis of area measurement with other studies on foramen magnum

Authors (Year)	Foramen magnum area (mm ²)
Murshed <i>et al.</i> [12]	931.7
Acer <i>et al.</i> [21]	760
Gapert <i>et al.</i> [2]	862.41
Ukoha <i>et al.</i> [23]	857
Singh and Talwar [20]	733
Shepur <i>et al.</i> [19]	748.6
Kumar <i>et al.</i> [11]	876.88
Present study (2018)	757.41

DISCUSSION

Foramen magnum is a passage between the cranial cavity and vertebral canal. It is formed by the interaction of bony ligaments and muscular structures forming the complex cranio vertebral junction. Bony parameter of foramen magnum is needed for transcondylar approach. Morphometric dimensions of foramen magnum also have an etiological significance in herniation of cerebellar tonsil, in various intracranial surgical approaches, to identify fire victims in forensic medicines. Understanding the importance of foramen magnum the findings of the present study were compared with previous studies. In our study of foramen magnum, the mean antero-posterior and transverse diameters in 50 skulls were 34.08±2.25 mm and 28.17±2.85 mm similar to study on Brazilian skulls, which also shown that the mean antero-posterior diameter was 35.22±3.3 mm and

the mean transverse diameter was 30.3 ± 2.0 mm^[22]. Our morphometric study of foramen magnum showed slightly fewer dimensions than the study done on 100 Nigerian skulls in 2011, which showed a mean Antero-posterior diameter of 36.2 ± 2.3 mm and a transverse diameter of 30.0 ± 2.5 mm^[23]. This results show variations in our studied due to racial differentiation. Various other morphometric measurement of foramen magnum also revealed that antero posterior diameter is more than the transverse diameter as in our study. The measurement of antero-posterior and transverse diameter in our study were same as previous studies done by Borelli *et al.*^[16], Kanchan *et al.*^[17]; Santosh *et al.*^[18].

Measurement of an area on foramen magnum in our study was 757.41 mm², which was similar to morphometric previous study done by Shepur *et al.*^[19], Singh and Talwar^[20] and Acer *et al.*^[21]. Uthman *et al.*^[24] also reported that foramen magnum area was the best discriminant parameter for sex determination with accuracy of 69.3%. Foramen magnum undergoes various evolutionary changes due to its different osteological features^[25]. There were great variations in morphological shapes of foramen magnum. The morphological variations of the foramen magnum found in our study were oval (48%), rounded (19%), hexagonal (9%), pentagonal (12%), diamond (9%) and irregular (3%) shapes. Radhika *et al.*^[15] also observed oval as main type 64%, while it is tetragonal in other studies. Knowledge of this morphological shape is very important as for surgeons as it was difficult to explore anterior portion of foramen magnum in ovoid type^[26]. In some other study of Mushed *et al.*^[12], Chetan *et al.*^[13], Radhakrishan *et al.*^[14] the round shape was commonly observed. A study done on CT images by Edril *et al.*^[27] showed CT images parameters are higher in males as compared to females similar to our findings. This type of prospective studies gives a morphometric references to various types of foramen magnum in Indian population, as there is a great variations regarding literature available on the morphological dimensions of foramen magnum.

CONCLUSIONS

The morphometric knowledge regarding foramen magnum is very important for various surgical procedures of posterior cranial fossa. This type of morphometric study gives us significant parameters to determine feasibility of transcondylar approaches to

prevent complications like hemorrhage and injury to vital structures.

Studies of foramen magnum in skull is very important in various field due to its great clinical significance but the available data is scanty and is at variance with one another so additional studies are required to form some standard parameters.

CONTRIBUTION OF AUTHORS

Research concept- Dr. Pratishtha Potdar

Research design- Dr. Arjun Kumar

Supervision- Dr. Kuldeep Singh

Materials- Dr. Arjun Kumar

Data collection- Dr. Jagmohan Singh Dhakar

Data analysis and Interpretation- Dr. Arjun Kumar

Literature search- Dr. Jagmohan Singh Dhakar

Writing article- Dr. Pratishtha Potdar

Critical review- Dr. Kuldeep Singh

Article editing- Dr. Pratishtha Potdar

Final approval- Dr. Kuldeep Singh

REFERENCES

- [1] Standring S. Gray's anatomy. The anatomical basis of clinical practice. 39th ed. London: Elsevier Churchill Livingstone; 2005: 460.
- [2] Gapert R, Black S, Last J. Sex determination from foramen magnum. *Int. J. Legal Medicine*, 2008; 123(1): 25-33.
- [3] Faruqi N. A Human osteology. Chapter 40. 2nd edition CBS publishers and Distributors Pvt. Ltd, 2011; pp. 396-428.
- [4] Kanodia G, Parihar V, Yadav R, Bhatele R, Sharma D. Morphometric analysis of posterior fossa and foramen magnum. *J. Neurosci. Rural Pract.*, 2012; 3(3): 261-66.
- [5] Kanchan T, Gupta A, Krishan K. Craniometric analysis of foramen magnum for estimation of sex. *Int. J. Med. Health, Biomed. Pharm. Eng.*, 2013; 7(7): 111-13.
- [6] Suazo G, Russo P, Zavando M, Smith RL. Sexual dimorphism in the foramen magnum dimensions. *Int. J. Morphol.*, 2009; 27(1): 21-23.
- [7] Edwards K, Viner MD, Schweitzer W, Thali MJ. Sex determination from the foramen magnum. *J. Forensic Radiol. Imaging*, 2013; 1(4): 186-92.
- [8] Patel R, Mehta CD. Morphometric study of foramen magnum at the base of human skull in South Gujrat. *J. Dental Med. Sci.*, 2014; 13(6): 23-25.

- [9] Howale DS, Bathija A, Gupta S, Pandit D. Correlation between cranial index and foramen magnum index in human dried skulls. *Glob. J. Res. Anal.*, 2014; 3(1): 03-06.
- [10] Singh P, Oberoi S, Gorea R, Kapila A. Age Estimation in old individuals by CT scan of Skull. *J. Indian Acad. Forensic Med.*, 2004; 26(1): 1-4.
- [11] Kumar A, Dave M, Anwar S. Morphometric evaluation of foramen magnum in dry human skulls. *Int. J. Anat. Res.*, 2015, 3(2): 1015-23.
- [12] Murshed KA, Emine A, Tuncer I. Morphometric evaluation of the foramen magnum and variations in its shape: a study of CT images of normal adults. *Turk. J. Sci.*, 2003; 33: 301-06.
- [13] Chethan P, Prakash JA, Murlimanju BV, Prashanth KV. Morphological analysis and morphometry of the foramen magnum: an anatomical investigation. *Turkish Neurosurg.*, 2012; 22(4): 416-19.
- [14] Radhakrishna SK, Shivarama CH, Ramakrishna A, Bhagya B. Morphometric analysis of foramen magnum for sex determination in south Indian population. *Nitte Univ. J. Heal. Sci.*, 2012; 2(1): 20-22.
- [15] Radhika PM, Shetty S, Prathap KJ, Sheshgiri C, Jyothi KC. Morphometric study of the foramen magnum in adult human skulls in Indian population. *Asian J. Med. Clin. Sci.*, 2014; 3 (2): 68-72.
- [16] Borelli D, Melo NS, Lima RS. Morphometry and spatial correlation of the foramen magnum and spinal cord through MRI. *J. Morphol. Sci.*, 2012; 29(2): 87-90.
- [17] Kanchan T, Attiku Y, Dixit PN, Kotian MS. Sex estimation from foramen magnum dimensions in an Indian population. *Journal of forensic and legal medicine*. 2012; 19: 162-67.
- [18] Santosh CS, Vishwanathan KG, Gupta A, Siddesh RC, Tejas J. Morphometry of the Foramen Magnum: An Important Tool in Sex Determination. *J. Med. Health Sci.*, 2013; 4(2): 88-91.
- [19] Shepur MP, Magi M, Nanjundappa B, Havaladar PP, Gogi P, et al. Morphometric analysis of foramen magnum. *Int. J. Anat. Res.*, 2014; 2(1): 249-55.
- [20] Singh G, Talwar I. Morphometric analysis of foramen magnum in human skull for sex determination. *Hum. Bio. Rev.*, 2013; 2(1): 29-41.
- [21] Acer N, Sahin B, Ekinci N, Ergur H, Basaloglu H. Relation between intracranial volume and the surface area of the foramen magnum. *J. Cranio Fac. Surg.*, 2006; 17: 326–30.
- [22] Manoel C, Prado FB, Caria PHF, Groppo FC. Morphometric analysis of the foramen magnum in human skulls of brazilian individuals. Its relation to gender. *Braz. J. Morphol. Sci*, 2009; 26(2): 104-08.
- [23] Ukoha U, Egwu O, Okafor I, Anyabolu A, Ndukwe G, et al. Sexual Dimorphism in the Foramen Magnum of Nigerian Adult. *Int. J. Biol. Med. Res.*, 2011; 2(4): 878-81.
- [24] Uthman AT, Rawi NA, Timini JA. Evaluation of foramen magnum gender determination using helical CT scanning. *Dento. Maxillofacial. Radiol.*, 2012; 14: 197-202.
- [25] Sarthak J, Batham IK. Evaluation of foramen magnum in gender determination using helical CT scanning in Gwalior population. *Int. J. Med. Res. Rev.*, 2016; 4(3): 357-60.
- [26] Nevell L, Wood B. Cranial base evolution within the hominin clade. *J. Anat*, 2008; 212; 455-68.
- [27] Edril FH, Saban V, Cimen M, Isik O. Morphometric Evaluation of the foramen magnum by CT. *Ericyes Med. J.*, 2010; 32(3): 167-70.

Open Access Policy:

Authors/Contributors are responsible for originality, contents, correct references, and ethical issues. SSR-IJLS publishes all articles under Creative Commons Attribution- Non-Commercial 4.0 International License (CC BY-NC). <https://creativecommons.org/licenses/by-nc/4.0/legalcode>

